

ACTA

ORTHOPAEDICA ET TRAUMATOLOGICA

HELLENICA

SPECIAL ISSUE

Hand Surgery and Microsurgery in Greece - Part 1

HISTORICAL ARTICLE

- The whole true behind Schumann's self-injury. A tragedy in the life of a musical genius

ORIGINAL ARTICLES

- Treatment of radiocarpal dislocations or fracture-dislocations based on a new classification scheme
- Vascularized bone grafting from the dorsal distal radius based on 4th extensor compartment artery for Kienböck's disease. Current concepts and a new surgical technique
- Ligament reconstruction and tendon interposition arthroplasty for the treatment of 1st Carpo-Meta-Carpal joint arthritis
- Traumatic brachial plexus injuries: our experience on 485 surgical cases

REVIEW ARTICLE

- Kienböck disease, current issues



Official Journal of the
HELLENIC ASSOCIATION OF ORTHOPAEDIC SURGERY AND TRAUMATOLOGY
Athens Academy Award 2004

HAOST EXECUTIVE BOARD

President	Athanasios Th. Kostakos
Past President	Panayiotis J. Papagelopoulos
President Elect	Theodoros P. Kormas
Vice President	Athanasios Ch. Badekas
Secretary General	Olga D. Savvidou
Treasurer	Emanouil V. Brilakis
Deputy Secretary	Zoe Ch. Dailiana
Council Members	Leonidas G. Nikolakakos
	Ekaterini D. Manta

HCOS EXECUTIVE COMMITTEE

President	Aristides B. Zoubos
Vice President Ex Officio	Theodoros P. Kormas
Vice President	Nikolaos G. Markeas
Secretary	Pavlos Christogeorgos
Member	Anastasios Mourikis
Residents Delegate	Dimitrios Z. Tzefronis

PRESIDENTS OF HAOST SECTIONS

Reconstructive Surgery:	Vasileios Bitounis
Oncology:	Ioannis Papakostas
Foot & Ankle:	Alexandros Eleftheropoulos
Spine:	Sotiris Papastefanou
Shoulder & Elbow:	Emmanuel Fandrides
Research:	Marios Likissas
Infections:	Konstantinos Malizos
Trauma:	Georgios Gouvas
Paediatric Orthopaedics:	Charalampos Konstantoulakis
Primary Health Care:	Pavlos Christogeorgos
Sport Injuries:	Dimitrios Tsoukas



EDITOR IN CHIEF

Nikolaos Papaioannou

ASSISTANT EDITORS

Theodoros Grivas

Nikolaos Markeas

Stamatios Papadakis

Ioannis Triantafyllopoulos

EDITORIAL BOARD

Dimitrios-Sergios Evangelopoulos

Dimitrios Economopoulos

Efstathios Chronopoulos

Konstantinos Kateros

Kalliopi Lampropoulou-Adamidou

Andreas Mavrogenis

SCIENTIFIC COMMITTEE AND REVIEWERS

Georgios Babis	Khaldi Lubna
Athanasios Badekas	Georgios Machairas
Alexia Balanika	Evangelos Magnisalis
Christos Baltas	Konstantinos Malizos
Hippocrates Chatzokos	Panayiotis Megas
Anastasios Christodoulou	Dionysios Mouzakis
Konstantinos Demetzos	Pantelis Nikolaou
Ioannis Dionysiotis	Elias Panayiotopoulos
Ismi-Niki Dontas	Georgios Panayiotakopoulos
Eleni Douni	Andreas Panagopoulos
Panayiotis Efstathiou	Panayiotis Papaggelopoulos
Ioannis Feroussis	Apostolos Papalois
Antonis Galanos	Georgios Papanikolaou
Ioannis Gliatis	Athanasios Papavassiliou
Michael Hantes	Georgios Petsatodis
Anastasios Kanellopoulos	Spyridon Pnevmatikos
Theofilos Karachalios	Georgios Sapkas
Aikaterini Katsalira	Symeon Tournis
Konstantinos Kazakos	Georgios Trovas
Georgios Kontakis	Eleftherios Tsiridis
Theodoros Kormas	Minos Tyllianakis
Anastasios Korobilias	Eleni Vavouraki
Dimitrios Korres	Theodoros Xenakis
Irene Lambrinouadaki	

INSTRUCTIONS TO AUTHORS

1. Scope

“Acta Orthopaedica Et Traumatologica” is the official journal of the Hellenic Association of Orthopaedic Surgery and Traumatology, first published in 1948. This revived edition of Acta Orthopaedica Et Traumatologica, published in English, aspires to promote scientific knowledge in Orthopaedics and Traumatology worldwide. It is a peer-reviewed Journal, aiming at raising the profile of current evidence-based Orthopaedic practice and at improving the scientific multidisciplinary dialogue. Acta Orthopaedica Et Traumatologica Hellenica presents clinically pertinent, original research and timely review articles. It is open to International authors and readers and offers a compact forum of communication to Orthopaedic Surgeons and related science specialists.

2. Language

English is the official language of the journal. All submitted manuscripts should be written in English.

3. How to submit a paper

All submissions for peer-review should be performed online through the journal or visit the journal site: www.eexot-journal.com

The Editorial office and the Editor-in-chief will perform the initial assessment of the manuscript and if the manuscript is suitable for the journal and the submission is complete, it will be sent to the relative reviewers. The reviewing process that is followed is double blinded. During on-line submission, authors can enter the name/s of non-preferred reviewers.

The time allocated for reviewers to assess the manuscript and submit their recommendation is three weeks. The Editor-in-chief makes the final decision for publication. The Editorial office will communicate the reviewer’s comments and the decision to the authors.

4. Manuscript originality and copyright

The submitted manuscript should be original, should not contain previously published material and should not be under consideration for publication in another journal. The submission needs to be approved by all co-authors and in case of original research a ‘guarantor’ of the study is required. As ‘guarantor’ may be considered a senior author that is deemed to take overall responsibility for all aspects of the study (ethics, originality, consent, data handling, and all aspects of Good Medical Practice). The ‘guarantor’ of the study does not necessarily need to be the corresponding author. The journal will not hold legal responsibility should there be any claim for compensation.

All authors need to sign the copyright transfer form (link) and must have made substantial contributions as established by the ICMJE (<http://www.icmje.org>).

5. Conflict of interest disclosure

Each author needs to disclose any type of financial interest that is related to the study and might create a potential conflict. Funding of the study needs to be disclosed.

If there is no conflict of interest, this should be

stated in the manuscript before the Reference section as follows: "The authors declared no conflicts of interest".

6. Research ethics and compliance

The journal follows the guidelines of the International Committee of Medical Journal Editors (www.icmje.org). For all original articles a statement in the text of approval from the local ethics committee, a statement that research was performed according to the ethical standards as described by the Declaration of Helsinki and a statement that informed consent for participation in the study was obtained from all subjects, are required. In case of study with animals the following statement needs to be added in the text: "All applicable international, national, and/ or institutional guidelines for the care and use of animals were followed".

7. Permissions and plagiarism

For the use of any figures already published elsewhere the authors are required to obtain written permission from the copyright owner(s) and to submit the evidence in the submission process. Plagiarism will not be accepted in any case. Dedicated software will be used on this purpose; manuscripts with plagiarism will be returned to the corresponding author without consideration for peer review.

8. Types of manuscript

The journal accepts the following types of articles:

- **Original articles:** The paper needs to offer new knowledge on Orthopaedics and Traumatology. The conclusions need to be sound and supported by statistical analysis. When the accuracy of a diagnostic test is assessed, following the Standards for Reporting of Diagnostic Accuracy (STARD) flow diagram (<http://www.stard-statement.org>) is suggested. A structured abstract of 250 words, 3-5 keywords, text up to 4,500 words, figures (up to four figures or eight figure parts), a maximum of six tables, a maximum of fifty references and a maximum of seven authors are required for original articles.
- **Review Articles:** The journal may accept systematic reviews, meta-analyses, literature reviews and

historical reviews of a subject. An unstructured abstract of 200 words, 3-5 keywords, text of no more than 6,000 words, figures (up to eight figures), a maximum of six tables, a maximum of a hundred references and a maximum of six authors are required for review articles.

- **Basic Science.** Basic science manuscripts could be either original or review articles on recent research achievements. Authors should follow the corresponding instructions according to the type of manuscript (original or review).
- **Monographs.** Highly detailed and thoroughly documented studies or reviews written about a limited area of a subject or field of inquiry. Monographs will be published on special issues.
- **Pictorial Essays:** The purpose of pictorial essays is to provide a teaching message through high quality images. A brief text is required to accompany figures. An unstructured abstract of 200 words, 3-5 keywords, text of no more than 6,000 words, a maximum of 15 figures, a maximum of 6 tables, a maximum of a 100 references and a maximum of 4 authors are required for pictorial essays.
- **Case Reports:** Reports on new or very rare clinical cases on Orthopaedics, Orthopaedic Pathology and Trauma, new diagnostic criteria, new therapeutic methods with proven result. Maximum 1,500 words, 10 references and 6 figures. Abstract up to 100 words.
- **Letters to the editor:** Communication to the editor is welcomed and will be published if they offer pertinent and/ or constructive comment on articles published in the *Acta Orthopaedica Et Traumatologica Hellenica*. Letters are published at the discretion of the Editorial team and should be received within three months after on-line publication of an article. Following acceptance, letters will be sent to authors for response. Letter communications should include text of no more than 500 words, up to 2 figures and 10 references, without any abstract or keywords and a maximum of 3 authors.

9. Manuscript organization

A manuscript must contain the following parts for submission:

- **Cover letter:** Each manuscript needs to be accompanied by a cover letter signed by the corresponding author on behalf of the rest of the authors stating that the article is not under consideration in another journal. In case of article resubmission a point-by-point answer to the reviewer's comments needs to be submitted with the cover letter.
- **Title page:** It includes the title of the manuscript, the names, affiliations and e-mail addresses of all authors and the affiliation, address, e-mail address, telephone and fax number of the corresponding author. The name and affiliation of the 'guarantor' of the study needs to be included in the title page for original articles.
- **Blinded manuscript:** Blinded title page including only the title of the manuscript with no affiliation.
- **Abstract:** An abstract presenting the most important results and conclusions is required for all papers except for Letters to the Editor. For Original Articles the abstract needs to be structured as follows: Purpose, Material and Methods, Results, Conclusions. For Reviews and Pictorial Essays, a 1-paragraph unstructured abstract is required.
- **Keywords:** Below the abstract, 3 to 5 keywords are required. Keywords need to be selected from the Medical Subject Headings (MeSH) database of the National Library of Medicine.
- **Text structure:** the text of the Original Articles needs to be organized as follows: Introduction, Materials and Methods, Results and Discussion. Review Articles, and Pictorial Essays require Introduction and Discussion sections only.
- **Fonts:** The suggested font is double spaced Times New Roman (12 pt).
- **Abbreviations:** Abbreviations should be used as minimum as possible. When used, they should be defined the first time they are used, followed by the acronym or abbreviation in parenthesis.
- **Acknowledgements, sponsorships and grants:** Acknowledgements need to be placed at the end of the manuscript before 'References' section. Any grant received or sponsorship from pharmaceutical companies, biomedical device manufacturers or other corporations whose products or services have been used needs to be included in the Conflicts of

Interest Form and also mentioned in acknowledgements section.

- **Measurement Units:** All measurements should be mentioned in international units (SI). The full stop should be used as a decimal (i.e. 3.5 cm). Spaces should be added around the plus/minus symbol (i.e. 13.6 ± 1.2). There should not be any spaces around range indicators (i.e. 15-20) or equality/inequality symbols (i.e. $r=0.37$, $p<0.005$).

10. Figures and Tables

All figures and tables need to be cited in text consecutively in the order in which they appear in text into brackets and in Arabic numbers: i.e. (Fig. 1) and (Table 1). Figure parts need to be identified with lower case letters, i.e (Fig. 1a).

Figures need to be of high quality. Vector graphics, scanned line drawings and line drawings need to be in bitmap format and should have a minimum resolution of 1,200 dpi. Halftones (photographs, drawings or paintings) need to be in TIFF or JPEG format, up to 174 mm wide and up to 234 mm high and in minimum resolution of 300 dpi.

Patient anonymity should be ensured. All identifying data (name, identification numbers, initials) must be removed from text, images and tables. If it is mandatory for a patient's face to be included in the manuscript, the eyes should be sufficiently masked. If there is a possibility that a patient may be identified from a photograph or relevant legend and text, the patient's written consent should be submitted.

A figure caption and a table caption need to be added in the figure and table section respectively for each figure and table.

Tables should appear at the end of the main document, numbered in Arabic numerals, each on a different page. Each table should have a title describing its content. Abbreviations appearing in the table need to be explained in a footnote. All table columns must have a subhead that describes the type of data included in the column.

11. References

The accuracy of references is the responsibility of the authors.

References need to be cited in the text in the order in which they appear. The numbering needs to be in Arabic numbers and placed in the respective areas of text into square brackets i.e [1].

References that have not been published at the point of submission need to be cited with the respective DOI (digital object identifier) number given for on-line first articles.

All authors (surnames and initials of first name) should be listed when they are three or fewer. If authors are more than three, the first three authors should be listed, then 'et al.' needs to follow the name of the third author.

When a book chapter is cited, the authors and title of the chapter, editors, book title, edition, city and country, publisher, year and specific chapter pages should be mentioned.

For Online Document, the following should be mentioned: authors (if any), title of page, name of institution or owner of Web site; URL; dates of publication, update, and access.

Reference examples:

■ Journal article:

Triantafyllopoulos IK, Lampropoulou-Adamidou K, Schizas NP, et al. Surgical treatment of acute type V acromioclavicular joint dislocations in professional athletes: An anatomic ligament reconstruction with synthetic implant augmentation. *J Shoulder Elbow Surg* 2017; doi: 10.1016/j.jse.2017.05.032 Epub 2017 Jul 21.

or

Papaioannou NA, Triantafyllopoulos IK, Khaldi L, et al. Effect of calcitonin in early and late stages of experimentally induced osteoarthritis. A histomorphometric study. *Osteoarthritis Cartilage* 2007; 15(4): 386-95.

■ Book chapters:

Triantafyllopoulos IK, Papaioannou NA. The Effect of Pharmacological Agents on the Bone-Implant Interface. In: Karachalios Th. (ed). *Bone-Implant Interface in Orthopaedic Surgery*. Springer – Verlag, London 2014, pp 221-237.

■ Online document:

National Institute for Health and Care Excellence. Fractures (Complex): Assessment and Management. Available via www.nice.org.uk/guidance/ng37. Published Feb 2016. Updated Sept 2017. Accessed January 2014.

12. Review of manuscripts

Acceptance of manuscripts for publication is decided by the Editor, based on the results of peer review. Authors need to make proof corrections within 72 hours upon pdf supplied, check the integrity of the text, accept any grammar or spelling changes and check if all the Tables and Figures are included and properly numbered. Once the publication is online, no further changes can be made. Further changes can only be published in form of Erratum.

For new article submission visit
www.eexot-journal.com

CONTENTS

LETTER FROM THE GUEST EDITOR

39

HISTORICAL ARTICLE

The whole true behind Schumann's self-injury. A tragedy in the life of a musical genius
 Nikolaos G. Markeas, Athanasios Verdis

40-46

ORIGINAL ARTICLE

Treatment of radiocarpal dislocations or fracture-dislocations based on a new classification scheme
 Apergis E., Kyriakopoulos G., Bonatsos S., Maris S.

47-62

ORIGINAL ARTICLE

Vascularized bone grafting from the dorsal distal radius based on 4th extensor compartment artery for Kienböck's disease. Current concepts and a new surgical technique
 Frantzeska Zampeli, Emmanouil Fandridis, Sarantos Spyridonos

63-76

REVIEW ARTICLE

Kienböck disease, current issues
 Pantelis K. Mitsikostas, Sofia A. Syngouna, Ioannis D. Aifantis, Ioannis S. Palavos

77-83

ORIGINAL ARTICLE

Ligament reconstruction and tendon interposition arthroplasty for the treatment of 1st Carpo-Meta-Carpal joint arthritis
 Panagiotis N. Giannakopoulos, Konstantinos Kourkoutas, George Kasimatis, Nikolaos Vlachos-Zounelis

84-95

ORIGINAL ARTICLE

Traumatic brachial plexus injuries: our experience on 485 surgical cases
 N.K. Daoutis, A.D. Vasileiadis, S. Spyridonos

96-105

LETTER FROM THE GUEST EDITOR

It gave me great pleasure to accept the invitation of the Editorial Board committee of the Acta Orthopaedica Hellenica journal to coordinate the edition of a volume on Hand Surgery and Microsurgery.

I would like to refer to some milestones that were major breakthroughs for the evolution of Hand Surgery and Microsurgery in Greece.

Everything started in the 1960s when the Head of the Orthopaedic Department, of the University of Athens, in the "KAT" Hospital, Professor G. Hartofilakidis recognised and ardently supported the need for the development of the specialty of Hand Surgery.

In 1967, the first reimplantation of an amputated upper limb proximal to the elbow joint was accomplished by A. Giannikas and P. Ballas, while in the 1970s the team of P.N. Soucacos performed the first reimplantation of an amputated finger with microsurgery techniques.

In the mid 1980s, the Hand Surgery and Microsurgery Department in "KAT" Hospital was organised and headed by N. Daoutis and afterwards by N. Gerostathopoulos. This Department played a significant role in the evolution of Hand Surgery and Microsurgery and gave a high-level training to young orthopaedics in Greece.

During the same period, in 1989, a systematic three-month workshop in Microsurgery in laboratory animals started taking place in the Laboratory for Research of the Musculoskeletal System "Th. Garofalidis" of the University of Athens in the "KAT" Hospital. Since then, more than one thousand surgeons of various specialties have been trained in this lab workshop.

Similar workshops have been organized by the Orthopaedic Department, University of Ioannina, while Microsurgery workshops in lab animals are also organized on a regular basis at the "Soucacos" Orthopaedic Center at "Attikon" Hospital.

Nowadays, we have achieved mastery in Hand Surgery techniques such as brachial plexus surgery, new techniques on peripheral nerve lesions, free flap transfers, toe transfers, arthroscopic techniques, arthroplasties, and gradual expansion of operations on the entire upper limb.

At the moment, surgical teams specialized in Hand Surgery and Microsurgery with rich clinical, educational and scientific experience work in both the public and private health system.

Last but not least, I would like to thank all the authors who have accepted my invitation and contributed to this volume by submitting manuscripts of high quality.

Sincerely,
Sarantis G. Spyridonos

Head of Hand Surgery-Upper Limb & Microsurgery Department
"KAT" Hospital

The whole true behind Schumann's self-injury. A tragedy in the life of a musical genius

Nikolaos G. Markeas¹, Athanasios Verdis²

¹2nd Department of Orthopaedics, General Children's Hospital "P. & A. Kyriakou"

²Pedagogical Department of Secondary Education, National and Kapodistrian University of Athens, Greece

ABSTRACT

In the field of Music History, Robert Schumann has been established as the epitome of German Romanticism. His works transcend the classical form of his predecessors and reveal his internal mental passions that strive to express themselves. In any case, his life was full of frustrations and upheavals that disturbed his mental health. Attempting to improve his piano technique led him to self-injure his right hand, which obviously affected his compositions and musical choices. The interpretations of Schumann's psychosocial disorder pertain to a wide range of possible diagnoses, from schizophrenia and bipolar disorder to brain tumor and neurosyphilis. Mercury poisoning seems just as likely.

KEY WORDS: Robert Schumann, self-injury, extensor tendons, hand

Introduction

By the early 19th century, the works of Wolfgang Amadeus Mozart and Ludwig van Beethoven reigned over mainland Europe. At that time, gifted music composers, such as Franz Schubert, Felix Mendelssohn Bartholdy, Frédéric Chopin, and Robert Schumann, were forced to create new routes in their works, in order not to be measured against the eternal teenager from Salzburg or the creator of the unparalleled Ninth Symphony. The only way out

was simply to listen to the vibrations of their restless nature, or the intense passions that governed their thinking, and to turn them -alike alchemists- into valuable music sounds.

Robert Schumann represents German Romanticism, i.e. the movement of German-speaking countries in the late 18th and early 19th centuries that influenced Art in a variety of ways. His turbulent life, the frustrations, the mishaps, the hardships, and the upheavals that marked his earthly life, were

CORRESPONDING
AUTHOR,
GUARANTOR

Nikolaos G. Markeas MD, PhD
Director of 2nd Department of Orthopaedics,
General Children's Hospital "P. & A. Kyriakou", Athens
42 Sikelianou street, Egaleo
tel.: 6975856940
122 43 Athens
E-mail: markeasn@otenet.gr

certainly a source of inspiration for him and a cause for gratification for musicophiles. However, these upheavals contributed as well to his mental illness. Self-injury of his right hand, in an attempt to improve his piano technique, was a dramatic experience that narrowed his choices. As it was the case in Schumann's times, almost two centuries ago, the same issue is today a subject of scientific inquiry.

Schumann and the dawn of Romanticism in music

Contrary to what we think, Romanticism in the field of music made its appearance before Beethoven's death. Carl Maria von Weber's versatile and sophisticated works were a pleasant surprise for musicians in the early 19th century, who were accustomed to the classic form of the creator of "Fidelio". Without realizing it, and completely unsuspecting, they became the creators of a new artistic expression that ventured into mental passions, intrusive conflicts, introverted interactions that needed to express themselves.

Robert Schumann was born in these interesting times in Zwickau of Saxony on 8 June 1810. His father had relocated to this town six years earlier and had opened a bookstore and, together with his brother, a publishing house. In this atmosphere, infused with the "magic of speech", young Robert was raised until his 6th year, in a loving environment with predetermined choices [1].

The first contact with the world of music took place when he began studying under the direction of organist Johann Gottfried Kuntzsch. In 1819, he met the famous pianist Ignaz Moscheles in Karlsbad and was fascinated by his pianist skills. He vowed silently to follow suit and become a virtuoso himself. While still in high school in Zwickau, his father would often invite his friends home to see and enjoy the young talent who performed an endless repertoire of works of Joseph Haydn and Carl Maria von Weber either in their original form or transcribed for small orchestra (Fig 1).

After failing to pursue his ambitious plan to study with Weber, Robert turned to literature. He was only sixteen years old and he was already directing a literary association dedicated to the propagation of the works of Schiller, Walter Scott, Byron and



Figure 1. Robert Schumann's portrait in young age.

Jean Paul. It was then when he came across Schubert's lieder and tried to compose music based on verses of Byron, Schulze, and Eckert. However, with the death both of his father and his sister Emilie of an unknown mental illness, Robert's psychic universe suffered the first blows. At the same time, his mother's influence made him pursue law studies. It is obvious that from a very early age, this sensitive soul experienced moral challenges, discouragement, and mental anguish [2].

In 1828, at the age of 18, he moved to Leipzig to study Law. It was the same city where the echo of Johann Sebastian Bach's creative spirit was still intense. There, Robert met the famous teacher Friedrich Wieck, with whom he began piano lessons. The melancholic teenager rejoiced as soon as he saw at Wieck's house his daughter Clara, and was dazzled by her talent. This meeting sealed his destiny. He became a disciple of Wieck, stayed at his home, and was adopted by Clara with a bond that was constantly mutating and refreshing.

At the same time, he began composing his first brilliant solo piano works. In the 1830s-1840s, these attempts were the impetus for the birth of the grand compositions that made him immortal. Schumann

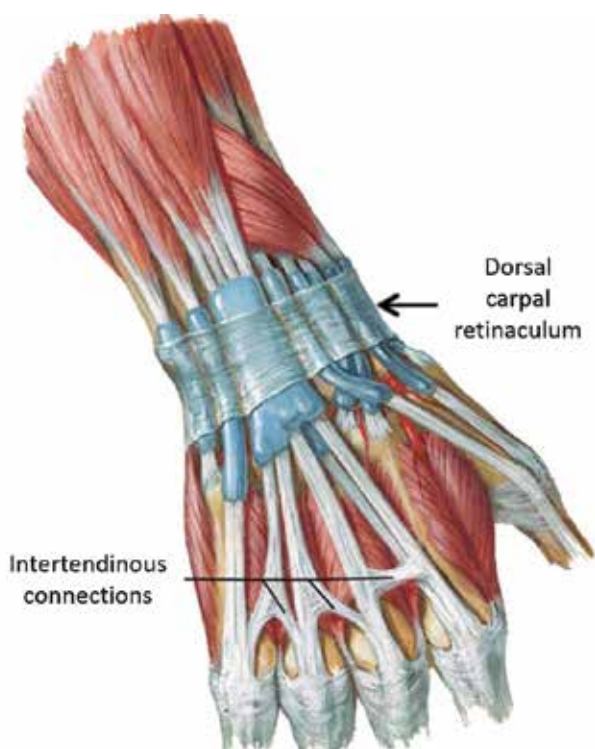


Figure 2. Anatomical structure of extensor tendons in a human hand.

left university for good and began collaborating with the music magazine *"Allgemeine Musikalische Zeitung"*. However, a dithyrambic review of the then unknown Frédéric Chopin was the reason for his dismissal [3].

Following these changes, Schumann's multi-faceted and restless spirit began to move in new directions. In 1833 he founded the magazine *"Neue Zeitschrift für Musik"*, intending to fight by all his power the "Philistines", i.e. the conservative elite of German intellectuals of his time. Contributors to the magazine, which was to become one of the most important publications of Romanticism in music, were Mendelssohn, Friedrich Wieck, and Clara, with various strange aliases. Schumann himself was the managing director of the journal, having signed his articles as "Florestan" or "Eusebius".

While working with Friedrich Wieck, an injury, he was responsible for, did not allow him to refine his technique, but instead determined his choices and affected his mental balance in a negative way [4].

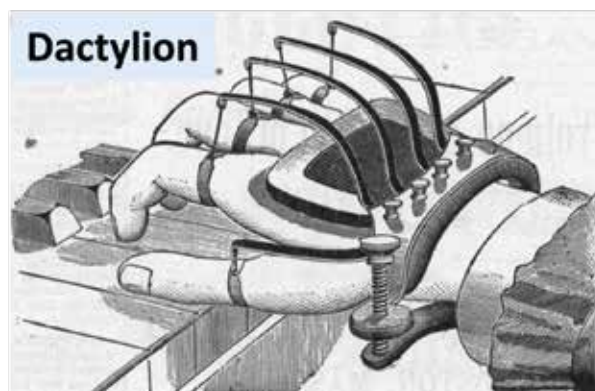


Figure 3. The device apparently used by Schumann for improving the independence of the fingers of his right hand and optimize his technique.

Self-injury

The need to perfect his piano technique urged Schumann to think beyond practicing. He felt that the flexibility of the fingers in his hands was undermined by the anatomical structure of the tendons. With complete ignorance of Anatomy, he realized that the attachment of the extensor tendons impeded the independence of his fingers (Fig 2). The tendons that extend the fingers are connected by ligaments (intertendinous connections), which, although they provide stability, help to prevent independent movement. It seems that this very issue still concerns soloists even today. Cases are reported that musicians have resorted to Orthopedic Surgeons or Plastic Surgeons for the cross-section of these ligaments and the release from their "tyranny".

At that time, various devices with the characteristic brand name "Dactylion" were promising the release of fingers bloodlessly, in a guaranteed and definite way (Fig 3). Their inventor is regarded to be Henri Herz (1803-1888), a pianist and composer, who profited by his method. All it took for the user was to follow closely the instructions and to be armed with nerve, persistence, and patience [3]. These devices, however, did not in any way guarantee that the result would be in line with the expectations of an exceptional pianist, such as Schumann, who was living in a state of fantastic and impractical thinking.

We are not entirely sure of what was the real cul-



Figure 4. The first page of “Neue Zeitschrift für Musik”, Issue 18 (October 28, 1853), with Schumann’s article for Johannes Brahms.

pirit behind Schumann’s injury of the ring finger of his right hand and essentially its stultification. Was the device fit to his hand incorrectly? Was his own tampering for a faster and better result did not work? Did he undergo surgery that unfortunately resulted in the rupture of his extensor tendon? The answer remains a mystery, although research that is more recent is shifting our thinking to other versions, which we will refer to in the following sections.

Eusebius and Florestan

In the early years of his married life with Clara, Schumann devoted all of his time to his work and his family needs. However, the gradual deterioration of his health, the injury to the hand that made him unable to play the piano, as well as the gigantic stress of psycho-mental disorders, forced him to work in a feverish page. As a result of his personal deadlocks, he became involved to spiritual requests, while at the same time he suffered from auditory



Figure 5. The mental asylum in Eendenich, near Bonne, where Schumann was hospitalized from 1854 until his death in 1856.

hallucination, overwhelmed by the “A-note anxiety” and vowed to occasionally receiving music messages from above, dictated by Schubert and Mendelssohn. Those days, he met Johannes Brahms.

No one can accurately guess the conflicting emotions that were wrestling within Schumann’s wounded soul, watching young Johannes rush into his home and fascinate the equally young and attractive Clara with his personality and unrecognizable genius. Jealousy plays dangerous games and, in vibrant delusional souls, it can lead to paranoid behavior. It was at the same time that Robert openly demanded that he would be held in an asylum. Without saying a word, he attempted to drown himself in the Rhine.

The issue of Robert Schumann’s mental illness has been of interest to researchers. The causes that led to it and the special circumstances for its resurgence are a matter of controversy even today. There were opposing views intended to soften the impression and restore his posthumous reputation. One such position was claimed by Eugenie, one of composer’s daughters, who in a book devoted to her father’s memory, attempted -without much persuasiveness- to support the case for his sanity. For her, Schumann’s established mental illness was the result of physical and psychological overwork, ruling out organic causes and hereditary predisposition [5].

A careful look at Schumann’s writings can illuminate some details in his thinking. These writings



Figure 6. Robert and Clara Schumann in a lithograph in 1847, with a personal dedication.

are not pieces of his personal communication or his diaries but his articles in the magazine "Neue Zeitschrift für Musik" (Fig 4). The fixation to sign his articles with a different pseudonym each time was no accidental. This option could certainly have been a clever tactic of him, so his criticism could sometimes be authoritarian and some other times lenient. However, the sobriety, the prudence, and the modesty that characterize Eusebius on one hand, and the anarchic impulsivity and romantic agitation that dominate Florestan's temperament, are the two Faces of Janus; two opposing personalities constantly fighting in his soul trying to express themselves; the earliest manifestations of a divisive psyche [5].

Schizophrenia or bipolar disorder or "gelatinous" tumor of the brain?

In recent years, the search for the Schumann's psycho-mental condition, informed by his symptoms



Figure 7. This daguerreotype (photograph) captures six of Schumann's eight children.

and peculiar behavior, has come together with the study of his musical works. It is certain that his disease inevitably affected his production in the late period of his life. It is argued that, even in his early works, traces of underlying disorder are visible. In the famous "Carnaval", Opus 9, the alternation of ideas and the relentless fluttering of matter from one subject to another can only be reconciled if we accept that they are creatures of a disturbed bipolar personality.

The perception of Schumann's music as a diagnostic tool has a long history. In 1906, the German psychiatrist Paul Julius Möbius, a pioneer of the idea that mental illness is due to inherited degeneration of the brain, published a pathological description regarding the composer [6]. Möbius claims, "By listening to Schumann's music we conclude that he was very nervous". He himself suggests that the underlying disease was, without a doubt, schizophrenia.

Other scholars echo the initial diagnosis first made by Franz Richarz, a physician at Schumann's sanatorium of Eendenich, where the composer remained for the last two years of his life (Fig 5). Richarz in his medical report mentioned progressive paraly-

sis, excessive fatigue, and fatal mental exhaustion as the cause of death. The truth is that Schumann's contemporaries supported this view, such as the violinist Joseph Joachim, to whom both Schumann and Brahms had dedicated their violin concerts [3]. There is no doubt that this report was later disseminated and prevailed to preserve Schumann's legacy. A recent paper by Janisch and Nauhaus supports the existence of a "gelatinous" tumor at the base of the brain [7]. The researchers claim that the composer was suffering from a colloid cyst, a craniopharyngioma, a chordoma, or a chordoid meningioma. While psychiatrists listen to his compositions to diagnose underlying disease, musicophiles use psychiatric diagnoses to understand his works.

Syphilis and Mercury

In 1950, British researchers Eliot Slater and Alfred Meyer were the first to put forwards the theory of Schumann's "manic depression" due to a neuro-syphilis attack. Their point was based on the ups-and-downs of his work, as in times of euphoria his compositions were more and more inspired, while in times of depression they were characterized by poor imagination [2].

When in 2006, 150 years after Schumann's death, medical records from the asylum of Eendenich were published in full (except for a few pages that were unfortunately lost during World War II), confirming investigators' thoughts: without doubt, Schumann had died of neurosyphilis [8]. Medical knowledge at that time could not diagnose the disease definitely, although its clinical symptomatology could have supported this diagnosis.

This diagnosis can even explain the clumsiness of his right hand, as neurosyphilis (or tertiary syphilis) infects the central nervous system and results in paralysis of both upper and lower extremities. In the early 19th century, *salvarsan* (which gave hope, years later, with the experiments of Paul Ehrlich) had not yet been discovered, as was the case with *penicillin* of Alexander Fleming, which gave the final blow against causative organism, the *Treponema pallidum* [9-11].


Schumann's infestation of syphilis is likely, con-

sidering his uncontrolled sexual activity before meeting Clara Wieck. After his marriage, he never committed adultery (Fig 6). He had always been an exemplary husband and father of eight children, struggling to assist in their upbringing (Fig 7). The most likely version for this sexually transmitted infection indicates the home-maid chosen by his father. The incubation lasted for several years until the disease began, as Schumann was living a prudent life.

However, even this version of events is not convincing. According to studies by musicologist and literary scholar Eric Sams, Schumann's clinical symptomatology during his hospital stay in Eendenich and the details of his death, point out that he was poisoned by mercury. Mercury pharmaceuticals were prescribed in small doses in those years for the treatment of syphilis and it was thus likely for the clueless patient to exceed the indicated dose and suffer the results of the effects of the element.

Nowadays, we know that peripheral neuropathy is at the forefront of the effects of mercury poisoning, while the consumption of organic mercury is usually accompanied by peripheral vision impairment, stinging or needle-like sensations in the extremities and mouth, loss of coordination, muscle weakness, and other impairments of speech and hearing, inevitably leading to death. It seems that Schumann's self-injury was not the only reason for the loss of his virtuosity [12-14]. It was preceded by the attack of neurosyphilis, the progressive manifestation of its symptoms and mercury poisoning, which often causes more woes than the expected therapy.

Conclusions

Medical records referring to psychiatric symptoms are difficult to make out because of the particular geopolitical conditions in which they occur. Schumann's complicated and incomplete correspondence, his music sheets, and medical diagnoses that we typically use to study his life, can have many interpretations. It is almost certain that his work and his tumultuous life will remain an unsolved mystery for years to come. So let us enjoy his inspirational compositions with no more second thoughts. 

REFERENCES

1. Wilhelm Joseph von Wasielewski: *Robert Schumann*, Dresden, 1858.
2. Beate Perrey: *The Cambridge Companion to Schumann*, Cambridge University Press, 2007.
3. Daverio John: *Robert Schumann, Herald of a "New Poetic Age"*, Oxford University Press, 1997
4. Emil Vuillermoz: *Histoire de la Musique*, translated in Greek by George Leotsakos, Hypodomi editions, Athens, 1978.
5. Berthold Litzmann: *Clara Schumann, an Artist's Life, based on material found in diaries and letters*, translated in Greek from 4th edition of Grace E. Hadow, MacMillan (editors), London, Breitkopf and Härtel, Leipzig, 1918.
6. The Encyclopaedia Britannica: *A Dictionary of Arts, Sciences, Literature and General Information*, 1911.
7. Jänisch W, Nauhaus G: Autopsy report of the corpse of the composer Robert Schumann: Publication and interpretation of a rediscovered document, *Zentralbl Allg Pathol* 1986; 132: 129-36.
8. Berlin M, Zalups RK, Fowler BA. Mercury. In: Nordberg GF, Fowler BA, Nordberg M, Friberg LT, editors. *Handbook on the Toxicology of Metals*. 3rd edition. Chapter 33. New York, NY, USA: Elsevier; 2007.
9. Hahn RD, Cutler JC, Curtis AC, Gammon A, Heymann E, Johnwick JH, et al: Penicillin treatment of asymptomatic central nervous system syphilis. 1. Probability of progression to symptomatic neurosyphilis. *Arch Dermatol* 1956; 74:355-66.
10. Fraser CM, Norris SJ, Weinstock GM, White O, Sutton GG, Dodson R, et al: Complete genome sequence of *Treponema pallidum*, the syphilis spirochete. *Science* 1998; 281:375.
11. Danielsen AG, Weismann K, Jorgensen BB, Heidenheim M, Fugleholm AM: Incidence, clinical presentation and treatment of neurosyphilis in Denmark 1980-1997. *Acta Derm Venereol* 2004; 84:459-62.
12. Garnier R, Fuster JM, Conso F: Acute mercury vapour poisoning. *Toxicological European Research*. 1981; 3(2):77-86.
13. Marra CM, Maxwell CL, Smith SL, Lukehart SA, Rompalo AM, Eaton M, et al: Cerebral spinal fluid abnormalities in patients with syphilis: association with clinic and laboratory features. *J Infect Dis* 2004; 189:369-76.
14. Simms I, Fenton KA, Ashton M, Turner KM, Crawley-Boevey EE, Gorton R, et al: The re-emergence of syphilis in the United Kingdom: the new epidemic phases. *Sex Transm Dis* 2005; 32:220-6.

READY - MADE
CITATION

Markeas NG, Verdis A. The whole true behind Schumann's self-injury. A tragedy in the life of a musical genius. *Acta Orthop Trauma Hell* 2020; 71(2): 40-46.

Treatment of radiocarpal dislocations or fracture-dislocations based on a new classification scheme

Apergis E., Kyriakopoulos G., Bonatsos S., Maris S.

Red Cross Hospital, Athens, Greece

ABSTRACT

Radiocarpal fracture-dislocations are the most debatable of carpal dislocations. The term radiocarpal fracture-dislocations has been used incorrectly for many previously reported cases. Thus, many questions arise concerning their incidence, terminology and classification. In this review, an attempt is made to determine the criteria based on which an injury can be classified as radiocarpal fracture-dislocation. Additionally, the surgical treatment of radiocarpal fracture-dislocations with combined access, allows for a relatively accurate description of osteoligamentous injuries, both on the palmar and on the dorsal side of the wrist. Four types of injuries in the dorsal and two types of injuries in the palmar dislocations are portrayed. Furthermore, a new classification is proposed based on five parameters: those of chronicity, pathoanatomy, direction, associated injuries and complexity.

KEY WORDS: Wrist, Radiocarpal, Dislocation, Classification, Pathological Anatomy

Introduction

Radiocarpal (RC) fracture-dislocations are relatively rare injuries, whose exact frequency is unknown. We will probably never find out the true incidence of these injuries, since there is no consensus as to which injuries should be named radiocarpal fracture-dislocations.

Due to the rarity of the injury most references, describe a relatively small number [1, 2, 3-7] or isolated cases [8-26]. At present, only a few reports involve more than 10 patients: the report by Nyquist and Stern [27] with 10 cases, by Mudgal et al [28]

with 12 cases, by Girard et al [29] with 12 cases and by Dumontier et al [30] with 27 cases throughout a 23-year period.

The literature reveals that pure RC dislocations are rare injuries, while the RC fracture-dislocations involving radial styloid fractures are the most frequent. In addition, the dorsal RC fracture-dislocations are much more common than their palmar counterpart [28, 30, 31], although it seems the opposite is true for pure radiocarpal dislocations.

As for more violent traumas, these injuries have been reported mainly in males and usually of young

CORRESPONDING
AUTHOR,
GUARANTOR

Apergis Emmanuel MD, PhD
Director of Orthopaedic Department. Red Cross Hospital-Athens
e-mail: apergis@gmail.com

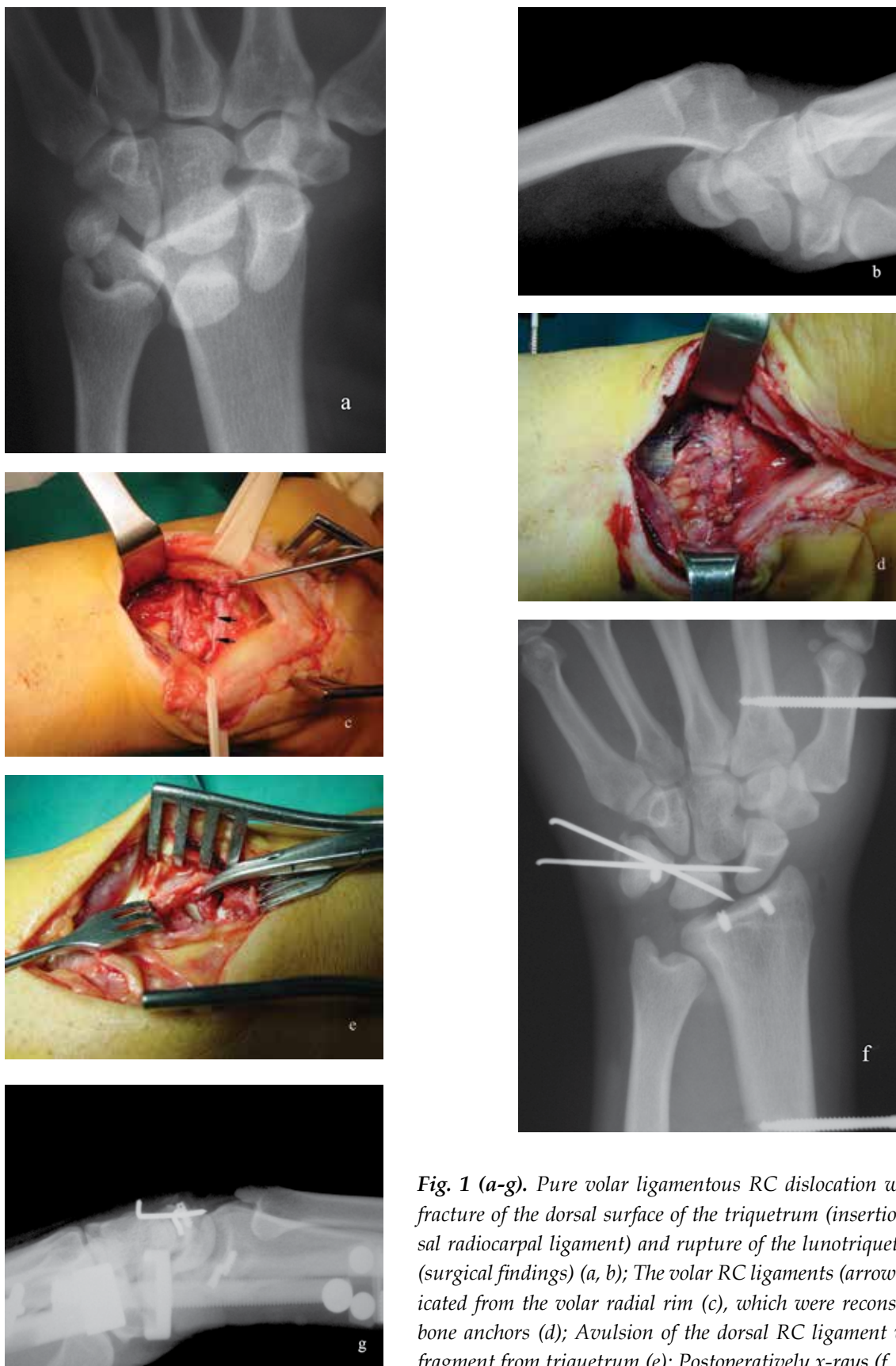


Fig. 1 (a-g). Pure volar ligamentous RC dislocation with avulsion fracture of the dorsal surface of the triquetrum (insertion of the dorsal radiocarpal ligament) and rupture of the lunotriquetral ligament (surgical findings) (a, b); The volar RC ligaments (arrows) were eradicated from the volar radial rim (c), which were reconstructed with bone anchors (d); Avulsion of the dorsal RC ligament with osseous fragment from triquetrum (e); Postoperatively x-rays (f, g).

age. In our series of 26 patients, the average age was 33.7 (range, 19-60) and only one was a woman, while in Dumontier's [30] series the percentage male/female was 4/1.

Stability of the radiocarpal joint

We know that wrist motion along the transverse plane (pronation-supination) is only possible if the wrist is not loaded. The range of passive rotational motion between radius and carpus varies from 40°-45° [32] and extrinsic tendon loading affects significantly the rotational stability of the wrist: the passive pronosupination laxity of the radiocarpal and midcarpal joint decreases from 45° to 10° by clenching the fist [32].

Many daily manual tasks are performed by rotation of the forearm. To perform these rotational tasks adequately, the relative motion between the radius and the carpus must be constrained within a limited amount of laxity. These constraints to rotation (which at the same time provide stability to the radiocarpal joint) consist of the concavity of the radial fossa, the dorsal and palmar capsuloligamentous structures that link the forearm to the carpus, the extensor compartments and the extrinsic tendons that cross the radiocarpal joint.

Ligamentous structures provide constraints in both rotational (pronosupination between radius and carpus) and translational (dorsopalmar and ulnar) displacement of the wrist.

Mechanism of injury

Radiocarpal dislocations are high energy injuries (fall from a height, traffic or industrial accidents) and therefore the patients rarely remember the exact mechanism of injury. This injury is a product of several factors: the anatomy of the articulating units, the strength and elasticity of the RC ligaments, the strength of the bony structures, the magnitude, rate of loading and position of the RC joint at impact [33, 34].

It is very possible, that independently of their direction, the pivotal separation of the wrist-forearm towards opposite directions is responsible. Specifically, when at the time of injury, the forearm is fixed in pronation and the wrist is violently supinated, a

dorsal RC dislocation may develop. Conversely, with the hand being fixed in pronation and the forearm violently supinated, a palmar RC dislocation may develop.

Apart from the rotation and the axial compression which are major components of the mechanism of injury, dorsiflexion and ulnar deviation [21, 23, 33], dorsiflexion and radial deviation [30, 35] or volar flexion and radial deviation [17] of the wrist, have all been implicated in the formation of injury. However, in many cases the mechanism of injury is extremely complex and hard to explain.

Terminology

Radiocarpal fracture-dislocations are the most debatable of carpal dislocations. The term RC fracture-dislocation has been incorrectly used in a considerable number of cases previously reported [36]. In a strict manner of speaking, dislocations of the RC joint should be either pure ligamentous injuries or dislocations associated with bony avulsions of ligamentous attachments.

There is agreement on terminology, only for pure ligamentous RC dislocations (**Fig. 1 a-g**). Confusion exists concerning the various types of fractures of the distal radius associated with dislocation of the RC joint. Various authors adopted different criteria to include injuries to the RC fracture-dislocation group: Dumontier et al [30] considered as RC fracture-dislocations, patients whose entire carpus had been dislocated volarly or dorsally to the radius, with fractures of the radial styloid more than one third of the width of the scaphoid fossa, provided that the ulnar half of the distal part of the radius was intact; carpal translations associated with a fracture of the volar or dorsal margin of the radius were excluded. On the contrary, others [37, 2, 33, 38, 36, 39], under the term RC fracture-dislocations comprised injuries characterized by dislocation of the RC joint in either dorsal or volar direction, which can be associated with radial and ulnar styloid as well as marginal rim fractures of the distal radius.

The main injury, from which RC fracture-dislocation must be differentiated, is the shearing marginal articular fractures of the distal radius (Type B according to AO classification or type II according to

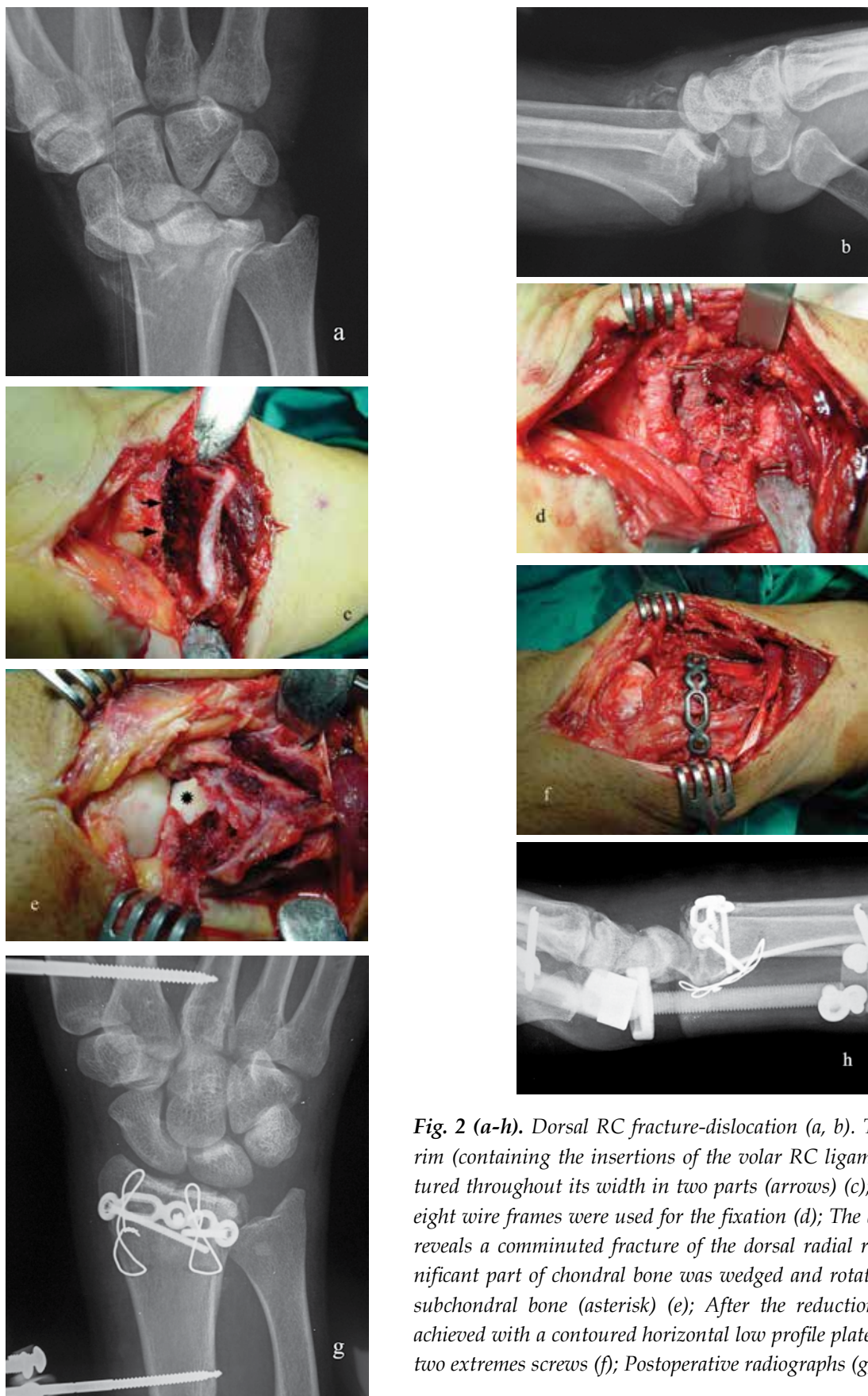


Fig. 2 (a-h). Dorsal RC fracture-dislocation (a, b). The volar radial rim (containing the insertions of the volar RC ligaments) was fractured throughout its width in two parts (arrows) (c); Two figures of eight wire frames were used for the fixation (d); The dorsal approach reveals a comminuted fracture of the dorsal radial rim while a significant part of chondral bone was wedged and rotated 90° into the subchondral bone (asterisk) (e); After the reduction, fixation was achieved with a contoured horizontal low profile plate using only the two extremes screws (f); Postoperative radiographs (g, h).

TABLE 1 Differences between RC fracture-dislocations and shearing fractures with wrist subluxation

	RC fracture-dislocation	Shearing fractures + wrist subluxation
Mechanism	Mainly rotational injury	Mainly compressive or axial load injury
Pathoanatomy	Injury at both sides of the RC joint (ligamentous or osseoligamentous)	One side injury (osseous)
Relation of osseous fragments with PCR	Fragments with no or only partial contact with PCR	Fragment in contact with PCR contains stabilizing ligaments
Reduction	Ease of reduction insecure maintenance	Reduction and fixation of the sizeable osseous fragment ensure joint stability

*RC = Radio-Carpal, PCR= Proximal carpal row

Fernandez classification) (Table 1). These injuries should not be confused with true RC fracture-dislocations, since, the fractured fragment containing significant ligamentous attachments, remains in contact with the proximal carpal row and its fixation restores the stability of the RC joint. However, most importantly they constitute one-sided injuries by definition, since the opposite cortex and the extrinsic RC ligaments must be intact [34, 40-42]. Thus, the distinction should not be based on the size of the osseous fragment alone, which either way is a subjective criterion, but whether there is an associated injury opposite the osseous fragment side. On the contrary, fractures of the dorsal radial rim associated with dorsal RC subluxation (frequently referred to as dorsal Barton) merit particular attention, as they are more related to RC fracture-dislocations. Lozano-Calderon et al [43] examined 20 such patients and found that 18 of them also had a wide spectrum of opposite volar injuries.

RC fracture-dislocations must also be differentiated from patterns of perilunate ligamentous injuries that have a radial styloid component [33], since they have a different mechanism of injury, pathoanatomy, treatment and prognosis.

Therefore, we believe that the prerequisite to consider these injuries as *radiocarpal dislocations* is the dislocation of the entire carpus volar or dorsal to the distal radius without fracture or with avulsion fractures at the insertion site of the ligaments (e.g. tip of the radial styloid, small ulnovolar fragment). Under the term *radiocarpal fracture-dislocations* we

should include patients: a) with dislocation of the RC joint associated with fractures which involve: the marginal cortical radial rims (volar and/or dorsal), the radial styloid or both, while there must be injuries (osseous and/or ligamentous) to both sides of the RC joint (dorsal and volar), b) whose radius metaphysis and the main portion of articular surface of the distal radius are intact, and c) with no associated intercarpal dislocations (the head of the capitate retains normal alignment with the distal lunate).

Idler [44] defined RC dislocation "as loss of articular contact between the proximal carpal row and distal radius not in association with a biomechanically significant fracture of the distal radius". Although the expression "biomechanically significant" raises much debate, we believe that the definition would be more accurate if the phrase: "and which also requires injury of at least both sides of the RC joint" is also added at the end.

However, there will always be cases in the grey area or questionable cases as to where they belong.

Pathologic anatomy of the injury

Understanding the pathologic anatomy of RC dislocations or fracture-dislocations is dependent on findings at surgical exposure. Since only few cases have been treated operatively with detailed description of their osseoligamentous injuries, the magnitude and spectrum of injuries are not exactly known. As a result, the extent of tissue compromise is often underestimated, leading to under-treatment and inferior results.

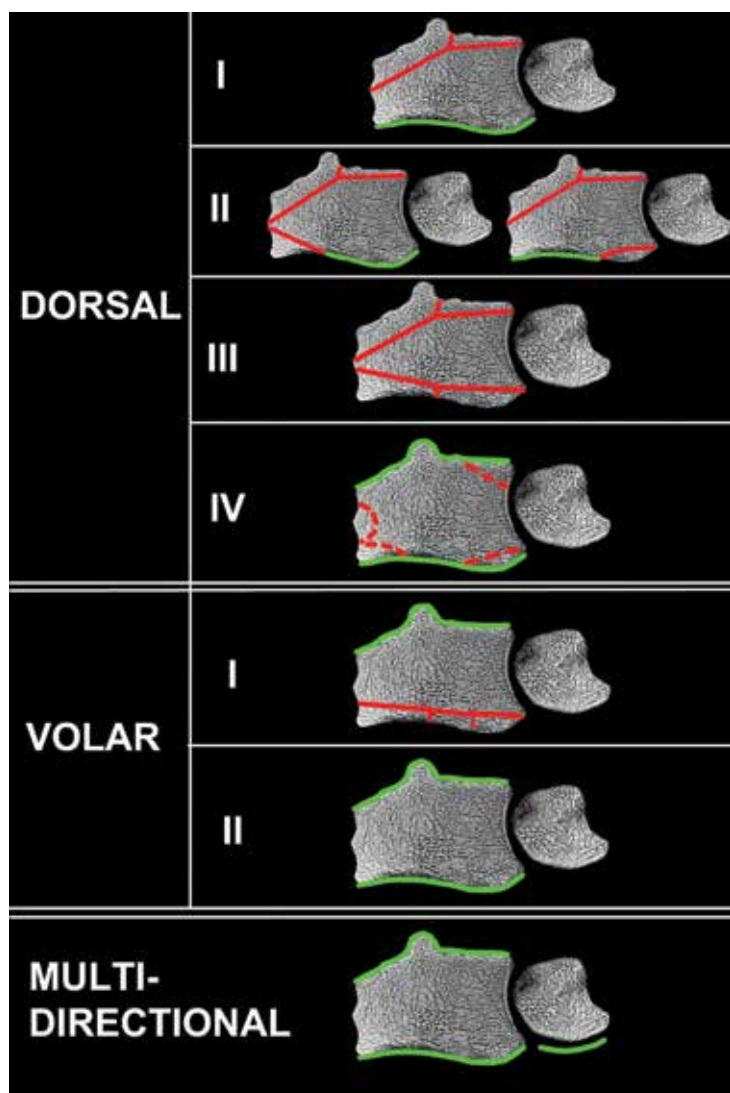


Fig. 3. The pattern of osseous (red lines) and ligamentous (green lines) disruption that was found in different types of dorsal, volar and multi-directional dislocations (see text for details).

RC fracture-dislocations are frequently associated with ulnar-sided injuries and only a few cases have been reported in the literature, where this injury was associated with dislocation of the distal radioulnar joint [1, 14, 30, 45, 46]. Rarely the dislocation is irreducible due to interposition of the flexor digitorum profundus of the small finger [30], or the extensor carpi ulnaris [46], or the dorsal part of the sigmoid notch where the dorsal radioulnar ligament is attached [45], or the flexor profundus tendons and the ulnar nerve and artery [14].

Wide displacement of any type of ulnar styloid fracture was also recognized as a significant risk for development of DRUJ instability [47, 48]. However, it is believed that the presence of an ulnar styloid

fracture is no longer considered an absolute indicator of DRUJ instability regardless of the fragment size and displacement [49,50], but only as a risk factor [51].

By excluding patients treated with methods that preclude the ability to describe the pathoanatomy of the injury, i.e. conservative treatment (5 patients) or closed reduction, percutaneous wires and/or external fixation (4 patients), twenty six patients were treated operatively, mostly with combined approach and their surgical findings were recorded. A single approach (1 volar and 1 dorsal) was used in 2 patients, a double approach (dorsal and volar) in 18, and a triple approach (dorsal, volar, ulnar) in 6 patients.

Four patients presented RC dislocations and 22 patients were of RC fracture-dislocation type. According to the direction of the dislocation, there were 19 dorsal (12 pure dorsal, 4 dorsoradial, 3 dorsoulnar), 5 volar and 2 multidirectional dislocations. All were closed injuries.

Surgical findings

1. In all cases, the ligamentous or osseo-ligamentous injuries involved both the dorsal and volar sides of the RC joint.

2. Of 22 patients with RC fracture-dislocations, 19 had fractures of the radial styloid, two patients had an osseous avulsion of the dorsoulnar corner of the distal radius and one patient had a combination of the above injuries.

3. Of 20 patients with fractures of the radial styloid, no one had fractured the entire radial styloid in dorsovolar dimension, independently of its width. The dorsal styloid segment was involved in 6 patients, the volar styloid segment in 3 patients and a combination of both segments was found in 11 patients. It was difficult to detect radiographically the combined segments of the fractured radial styloid; it was feasible only operatively.

4. Fractures of radial rims were either of compression or avulsion type depending on the direction of the dislocation. The direction of the dislocation coincided with the compression side of the radial rim, while the opposite radial rim had an avulsion type of fracture. Usually the osseous injury of the dorsal radial rim was double: there was a larger-sized fragment from the dorsal half of the radial styloid and a smaller-sized simple or comminuted fracture of the radial rim, ulnar to the Lister's tubercle, which involves the attachment of the DRC ligament (**Fig. 2 a-h**). The osseous fragments from the volar radial rim were sometimes rotated by 90°-180°, since the volar are shorter than the dorsal RC ligaments. There were 10 dorsal rim fractures, 4 volar and 4 combined dorsal and volar rim fractures.

5. A wide range of injuries of the proximal carpal row was noticed in 11 patients (42%), all of which were discovered intraoperatively: a) Osteochondral defects of adjacent bones of the proximal carpal row comprising the interosseous ligaments (3 patients;

two at scapholunate junction and one at lunotriquetral junction), b) isolated rupture of the interosseous ligaments (4 patients; two of scapholunate and two of lunotriquetral ligament), c) chondral defects of isolated bones (2 patients; at proximal scaphoid and at proximal lunate respectively), d) fractured bones (2 patients; lunate and triquetrum respectively).

6. In six patients, free osteochondral fragments were found intra- or extra-articularly, originating either from carpal bones or from the distal radius.

7. The RC ligaments were usually avulsed from the volar or dorsal radial rims, but in 7 patients they were avulsed from carpal bones with or without small osseous fragments. Specifically, the short radiolunate ligament was avulsed from the lunate (5 patients) and the dorsal RC ligament, was avulsed from the triquetrum (2 patients).

8. In 3 patients (2 with volar and 1 with multidirectional dislocation) there was an extensive rupture of the floor of the dorsal retinaculum, while in the patient with the multidirectional dislocation, the extensor and abductor pollicis longus were ripped-off from their musculotendinous junction, a finding indicative of the rotational component of the mechanism of injury.

9. Seventeen patients (65.3%) had associated injury of DRU joint (fracture through the base of the ulnar styloid in 14 patients, an osseous avulsion from the dorsal sigmoid notch of the dorsal radioulnar ligament in 3 patients and a Type IV rupture of the TFC in 1 patient).

10. The two multidirectional and one volar dislocation had in addition a complete rupture of the volar ulnocarpal ligaments.

Based on our surgical findings, we could define the pattern of osseo-ligamentous disruption as follows (**Fig. 3**):

In dorsal dislocations, there were roughly 4 types of injuries:

Type I (4 cases): Dorsally, a double osseous injury (separate fragments, radially and ulnarly to Lister's tubercle) and volarly a purely ligamentous injury.

Type II (7 cases): Dorsally a double osseous injury

TABLE 2 Classification of RC dislocations or fracture-dislocations

Chronicity	Pathoanatomy	Direction	Associated injuries	Complexity
a. Acute b. Gradually developed	RC dislocations a. Pure ligamentous b. Equivalent: Tip of radial styloid Ulnovolar fragment RC fracture-dislocations a. Radial styloid: Dorsal part Volar part Combination b. Radial rim: Dorsal rim Volar rim Both rims c. Dorsoulnar fragment	a. Dorsal b. Volar c. Ulnar d. Combinations e. Multidirectional	a. DRUJ b. UC ligaments c. Interosseous lig. of PCR d Osteochondral fragment e Carpal bone fractures f Tendons -muscles g Neural or vascular h Retinaculum	a. Reducibility b. Open or closed

*RC = Radio-Carpal, DRUJ= Distal radioulnar joint, PCR=Proximal carpal row, UC=Ulnocarpal ligaments

and volarly a double osseoligamentous injury. Usually the RC ligaments were detached from the ulnar side of the volar radial rim, while the radial side showed an avulsion fracture fragment. Less often, the reverse was true.

Type III (3 cases): Double osseous or comminution on both dorsal and volar sides.

Type IV (5 cases): Dorsal and volar, mainly ligamentous injuries, which were sometimes associated with small osseous fragments of avulsion type, originating from the radial styloid (either side) or from the dorsoulnar side of the radius.

In volar dislocations we found 2 types of injuries:

Type I (4 cases): Dorsally, purely ligamentous and volarly a double or comminuted osseous injury.

Type II (1 case): Purely ligamentous injuries on both sides.

In the two cases with **multidirectional dislocations**, we found a purely ligamentous injury on both sides with rupture of the ulnocarpal ligaments. One of those cases exhibited fracture of the tip of the radial styloid.

Classification

Two classification schemes have been discussed extensively in the literature: Dumontier et al [30]

classified RC dislocations into two types: type 1 included pure dislocations with or without fracture of only the tip of the radial styloid, a fracture involving less than one-third of the width of the scaphoid fossa, postulating that the RC ligaments were torn off the radius; type 2 included dislocations with associated fracture of the radial styloid involving more than one-third of the scaphoid fossa, postulating that most of the RC ligaments were still intact and attached to the radial styloid fragment.

Moneim et al [2] classified these injuries into type 1 and type 2 according to the integrity of the intercarpal ligaments. In type I dislocation, the carpus moves as one unit on the distal radius whereas in type II, an associated intercarpal dislocation is also present. He presented 7 cases and 3 of them were characterized as type II dislocations. According to the author, type II dislocations represent a more complex pattern, with a graver prognosis. It should however be noted, that all 3 cases characterized as type II RC dislocations were in fact trans-styloid perilunate injuries with volar dislocation of the lunate, from which RC fracture dislocations must be differentiated.

A third classification was that of Graham [38] who considered RC dislocations as “inferior arc” injuries, in addition to the existing injury patterns the “greater” and “lesser arc” injuries. He stated that

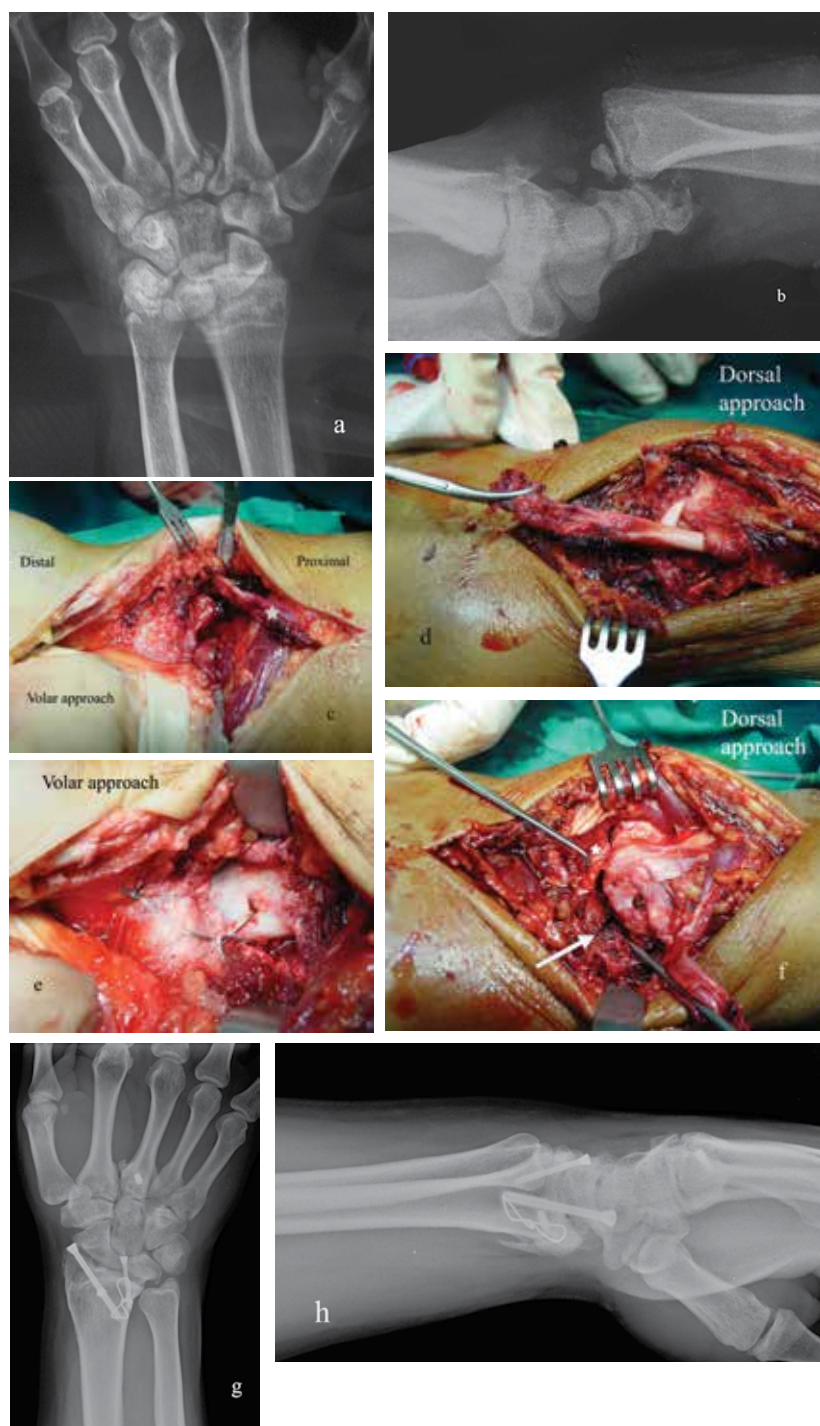


Fig. 4 (a-h). Volar RC fracture-dislocation associated with comminuted fracture of third metacarpal base (a, b); With volar approach, over pronator quadratus, a tendon stump was found (asterisk) (c); With dorsal approach it appeared to be the avulsed insertion of the ECRB from the base of the third metacarpal, a finding indicative of the magnitude of rotational force applied (d); The volar radial rim was divided into two parts, a smaller radial bone fragment containing RC ligaments and a larger one concerning the ulnovolar fragment which were fixated with a bone anchor and a figure-of-eight wire frame respectively (e); Despite volar direction of the dislocation the dorsal radial rim was separated in 2 fragments: a dorsoulnar (asterisk) and a dorsoradial fragment (arrow) which were fixed with 2 cannulated screws (f); Final x-rays 5 years post-injury (g, h)

RC dislocations could be classified as: a) purely ligamentous disruptions, b) dislocations with a “large fragment” styloid fracture, starting in the area of the previous physeal scar and entering the joint near the crista separating the scaphoid and lunate fossae and c) dislocations with a “small fragment” fracture, which represents avulsion or impaction injuries of the volar or dorsal margins of the distal radius.

Bilos et al [1] classified these injuries into four general types: dorsal, volar, radial, and ulnar, depending on the direction in which the carpus is displaced.

Bozentka and Beredjikian [52] commented on the need to include in the classification schemes other important factors, such as the direction, the presence of associated neurovascular injury and the presence of associated intercarpal ligamentous injuries.

Mainly relying on surgical findings, we propose a new classification based on five parameters (chronicity, pathoanatomy, direction, associated wrist injuries and complexity). Using this classification, a RC dislocation or fracture-dislocation should be presented with information on all five parameters (**Table 2**):

1. Chronicity: RC dislocations or fracture-dislocations are differentiated into acute and gradually developed. The latter group includes ulnar translation as sequelae of an already treated RC dislocation or a remote consequence after a subtle RC ligament rupture. Special mention deserve those cases presented in the literature, where the RC subluxation or dislocation was associated with a small fragment from the ulnovolar articular surface of the distal radius [3, 8, 15, 22, 25, 53, 54]. Since all these cases were closely reduced and after a period of time the subluxation recurred, they could belong to the gradually developed group.

2. Pathoanatomy: RC dislocations are differentiated into purely ligamentous or equivalent, which include the tip of the radial styloid or a small ulnovolar fragment. RC fracture-dislocations are differentiated according to the location of the fracture into: radial styloid (dorsal or volar part or combinations), radial rim (dorsal or volar or combined rims) and dorsoulnar fragment.

3. Direction: The direction of the dislocation

allows us to assume in a great extent the underlying lesions. Thus, these injuries are divided into dorsal, volar, ulnar, combinations (dorsoradial, dorsoulnar, radiovolar or ulnovolar) and multidirectional.

4. Associated injuries: These are related to concomitant injuries located in the vicinity of the dislocated wrist. They may concern DRUJ, ulnocarpal or interosseous ligaments, osteochondral fragments, fractured carpal bones, ruptured tendons or muscles (**Fig. 4 a-h**), neurovascular injuries and the dorsal retinaculum.

5. Complexity: This parameter clarifies if the dislocation is reducible or not and if the dislocation is open or closed.

Treatment

There have been reports of successful treatment with: closed reduction and casting [3, 12, 21, 30, 55], closed or open reduction and percutaneous pinning [56, 2, 7, 13, 23, 30], open reduction and casting [26, 57], open reduction and internal fixation with ligamentous repair [1, 2, 4, 8, 30, 58, 45, 36,59]. Due to the rarity of these injuries, there is no unanimously accepted method for their management.

Most of these dislocations are relatively easy to reduce, there are therefore cases that, being spontaneously reduced, escape diagnosis. The reported cases of a non-reducible dislocation are rare. In one case there was tendon interference [14], whereas in two other cases there was bone fragment interference [24, 45].

In several reports, mostly of isolated cases, closed reduction and cast immobilization are advised [2, 3, 12, 21, 25], in dorsiflexion for the dorsal and in palmarflexion for the palmar dislocations [25, 31]. However, RC dislocations treated non-surgically have been reported to develop palmar subluxation, ulnar translation DISI or VISI instabilities [3, 6, 9, 12, 13, 18, 21, 22, 36]. Certainly, everyone agrees that open, non-reducible dislocations and those accompanied by neurovascular injury must be managed with open reduction [60, 7]. Many reports [27, 28, 30, 33, 61-63], plead for open reduction since, if the RC ligamentous mechanism is not repaired, wrist function will be severely compromised with instability and/or subluxation later [59].

There are many cases in the literature that were initially managed with closed reduction and casting, but the wrist was subluxated early or late [2, 7, 13, 30]. In our series 7 out of 26 patients lost their reduction and were treated operatively with a delay of 4-20 days

If, for any reason, closed reduction is chosen, a basic requirement is to ensure that during the healing period, the anatomical alignment of the bones and joints will be preserved, in order for intraarticular fractures to be united without articular incongruity and most importantly, the RC joint to be axially aligned so that the ruptured ligaments can heal with proper tensioning. Alternatively, following closed reduction and once we have ensured that the RC joint has been anatomically reduced, we can immobilize the joint using K wire or external fixation.

There is no consensus as to which is the most appropriate approach for open reduction. The approach should be dictated by the direction of the dislocation, the fracture pattern, the associated carpal bone injuries, the presence of neurovascular injury and if we are dealing with an open or closed injury. Moneim et al [2] for cases necessitating open reduction proposed combined approaches. Mudgal et al [28] advised the use of palmar approach in the presence of a neurological defect, dorsal approach if the dorsal radial rim is involved and ulnar approach when the ulnar styloid requires fixation. Dumontier et al [30] believed that group 1 patients should be treated with reattachment of the ligaments through a volar approach. In group 2 patients, the ligaments are still attached to the radial fragment and in this group of patients, exact articular reduction should be performed through a dorsal approach. The Mayo clinic group, as quoted by Idler [44], has recommended palmar and dorsal approaches for ligament repair of the radiocarpitate, long radiolunate, ulnocarpal, and dorsal radiotriquetral ligaments.

Considering that by definition, RC dislocations or fracture-dislocations constitute double-sided injuries and that structures important for wrist stability are located both dorsally and volarly, we regard the combined approach as the most appropriate. In any case, of an acute dislocation or fracture dislocation, regardless of its direction, we consider the palmar

approach most important in order to repair the volar RC and ulnocarpal ligaments as well as any fractures of the volar radial rim, since these structures are crucial for wrist stability. In the majority of cases, dorsal approach is also required, especially in cases of compressive fractures of the dorsal radial rim, for the fixation of a potential dorsal part of a fracture of the radial styloid or to evaluate the integrity of proximal carpal row bones. Sometimes, when dorsally the injuries are purely ligamentous or are associated with small avulsed fragments or with subperiosteal detachment of the dorsal extensor compartments, then dorsal approach may be avoided, on the premise that the volar structures have been restored and the RC joint is maintained reduced and properly aligned for 6-8 weeks.

In cases of DRUJ instability or of a displaced fracture at the base of the ulnar styloid, a separate ulnar approach is frequently necessary.

Based on the literature and on personal experience, we consider the following steps as necessary for open reduction:

1. The patient is positioned supine on the operating table. An arm table is positioned beneath the affected extremity and the procedure is performed under tourniquet control. During anaesthesia, useful information concerning the magnitude and direction of dislocation can be acquired under image intensifier, through manipulation of the wrist (longitudinal traction and dorsal, volar, radial and ulnar displacement) with the forearm stabilized. In addition, PA and L radiographs with the RC fracture dislocation reduced are recommended.
2. Depending on the nature and the time elapsed from injury, an external fixator may be applied from the initial stages of operation, so that the wrist is kept in gross alignment and mild distraction, as it facilitates the exposure of the capsuloligamentous structures. The more delayed the injury's treatment is, the greater the need for the application of the external fixator at the initial stages of the operation. Its placement on the radial side of the wrist does not obstruct the impending approach.
3. The extended carpal tunnel approach is used to decompress both the carpal tunnel and

Guyon canal if needed and to fully evaluate the radio-volar injuries by displacing the FPL and the median nerve radially and the remaining flexor tendons ulnarly. The ulno-volar injuries are assessed by displacing the flexor tendons radially. Less often and depending on the extent of injuries, Henry's approach is sufficed. The joint is irrigated and the osseoligamentous lesions are recorded in detail. The palmar RC ligaments are either detached from their insertions to the volar radial rim or from carpal bones (usually the lunate) or avulsed with a small osseous fragment from their insertions. The reattachment of ligaments is achieved using non-absorbable sutures through transosseous holes or bone anchors that are inserted at the sites where the ligaments were detached. Depending on the size of the fractured fragments of the volar rim, their fixation is achieved using K-wires, small plates, or a wire-loop [64].

4. In cases where the healing capacity of the volar RC ligaments is questionable, especially in delayed cases, augmentation using tendon grafts is an option. Originally Rayhack et al [58] and more recently Maschke et al [65] described a cadaveric model for reconstructing the radioscapocapitate using the brachioradialis tendon, while Obafemi and Pensy [66] applied the same technique in a patient with palmar RC dislocation, in order to reconstruct the radioscapocapitate ligament and to reinforce the dorsal capsular repair.

5. The dorsal approach is longitudinal over Lister's tubercle, the third compartment is exposed if intact and the EPL tendon is displaced radially. The integrity of the dorsal retinaculum is recorded; if it is intact, subperiosteal elevation of the second and fourth compartments allow for a full evaluation of the dorsal injuries, since the dorsal capsule is already ruptured. At this stage and after joint irrigation, the injuries of the dorsal surface of the radius (from radial to ulnar) and the integrity of the chondral surfaces and the interosseous ligaments of the proximal carpal row bones are evaluated. Any entrapped chondral or osteochondral fragments are debrided or preserved for later transfixation. The integrity of the dorsal RC ligament must be checked throughout its course. In cases of compressive frac-

tures of the dorsal radial rim, the insertion of cancellous bone grafting is necessary to support the articular surface, using small buttress plates for fixation [28, 59, 67]. In cases with purely ligamentous injuries, small osseous fragments or subperiosteal detachment of the dorsal cortex, there are many alternative stabilizing methods including K-wires, bone anchors, screws or tension band wiring. Any injury of the proximal carpal row bones is treated accordingly and stabilized with K wires.

6. At the end of a stable reconstruction of the RC joint, the stability of the DRUJ is assessed. This information will be provided with passive anteroposterior glide of the distal ulna relative to the distal radius in positions of neutral rotation, full pronation and full supination, and whether the ballottement test demonstrates or not a hard end point. Thus, in cases of DRUJ instability or displaced fracture of the base of the ulnar styloid, tension band wiring or TFCC suturing are recommended [28, 59].

7. It is necessary, using the external fixator, to maintain the RC joint in a reduced position throughout the healing process for 6-8 weeks and to protect the reconstructed RC ligaments from slackening. In highly unstable injuries or when the reconstruction is suboptimal, an additional RC pinning is essential and is usually inserted percutaneously or through a small incision (protecting the sensory branches of the radial nerve), from the radial aspect of the radius and through the lunate towards the wrist.

8. The immobilization of the RC joint is maintained for 6-8 weeks and physiotherapy consisting of active and passive wrist mobilization must be initiated.

Complications


Limitations in the range of motion and reduction in grip strength are common occurrences regardless of the treatment method applied for these injuries. In addition, post-traumatic arthritis, instability findings and residual volar, dorsal or ulnar subluxation of the wrist, have been reported as possible complications after the management of these injuries [37, 7, 30, 44].

Ulnar translation [68] or ulnar translocation [31] is observed in cases of serious and generalized lig-

amentous injuries of both the palmar and dorsal sides of the wrist. It could be manifested as either pure ulnar translocation [9, 58, 69, 70, 71] or as sequelae of reduced palmar [15, 18, 22] or dorsal [19] RC dislocations, which were treated with closed or open reduction and inadequate reconstruction of the volar RC and ulnocarpal ligaments. Ulnar translocation of the wrist is more common with purely ligamentous injury patterns [13, 18, 22, 25, 30], while excessive minus variance of the ulna with deficient ulnar buttressing by the TFCC, may be a predisposing factor [58, 72].

Palmar translation of the wrist was found with

less ligament disruption than that required for ulnar translation, whereas in all cases of ulnar translation, there was a component of palmar wrist displacement [73].

Different methods of assessing ulnar translation have been reported. The methods using the center of the capitate head [74-76] as a carpal reference should not be used in type II injuries, because only the lunate-triquetrum complex is significantly displaced in these cases. In contrast, when using the lunate as a reference [77-79], if the wrist is slightly radially or ulnarly deviated, the measurements may be unreliable [73]. 

REFERENCES

1. Bilos ZJ, Pankovich AM, Yelda S Fracture-dislocation of the radiocarpal joint. *J Bone Joint Surg Am* 1977, 59:198-203
2. Moneim MS, Bolger JT, Omer GE Radiocarpal dislocation--classification and rationale for management. *Clin Orthop* 1985, 192:199-209
3. Bellinghausen HW, Gilula LA, Young LV et al Post-traumatic palmar carpal subluxation. Report of two cases. *J Bone Joint Surg Am* 1983, 65:998-1006
4. Le Nen D, Riot O, Caro P et al Luxation-fractures of the radiocarpal joint. Clinical study of 6 cases and general review. (In French) *Ann Chir Main Memb Super* 1991, 10:1:5-12
5. Mourikis A, Rebello G, Villafuente J et al Radiocarpal dislocations: Review of the literature with case presentations and a proposed treatment algorithm. *Orthopedics* 2008 31:386 DOI:10.3928/01477447-20080401-24
6. Naranja RJ, Bozentka DJ, Partington MT et al Radiocarpal dislocation: a report of two cases and a review of the literature. *Am J Orthop* 1998, 27:2:141-144
7. Schoenecker PL, Gilula LA, Shively RA et al Radiocarpal fracture-dislocation. *Clin Orthop* 1985, 197:237-244
8. Apergis E, Dimitrakopoulos K, Chorianopoulos K Late management of post-traumatic palmar carpal subluxation: A case report. *J Bone Joint Surg Br* 1996, 78:419-421
9. Arslan H, Tokmak M Isolated ulnar radiocarpal dislocation. *Arch Orthop Trauma Surg* 2002, 122:179-181 DOI:10.1007/s00402-001-0366-3
10. Ayekoloye CI, Shah N, Kumar A et al Irreducible dorsal radiocarpal fracture dislocation with dissociation of the distal radioulnar joint: a case report. *Acta Orthop Belg* 2002, 68:2:171-174
11. Dodd C.A. Triple dislocation in the upper limb. *Journal of Trauma* 1987, 27:11:1307.
12. Fehring TK, Milek MA Isolated volar dislocation of the radiocarpal joint. A case report. *J Bone Joint Surg Am* 1984, 66:464-466
13. Fennell CW, McMurtry RY, Fairbanks CJ Multidirectional radiocarpal dislocation without fracture: A case report. *J Hand Surg [Am]* 1992, 17:756-761
14. Fernandez DL Irreducible radiocarpal fracture-dislocation and radioulnar dissociation with entrapment of the ulnar nerve, artery and flexor profundus II-V-case report. *J Hand Surg [Am]* 1981, 6:456-461
15. Freeland A, Ferguson CA, McCraney WO Palmar radiocarpal dislocation resulting in ulnar radiocarpal translocation and multidirectional instability. *Orthopedics* 2006, 29:7:604-608, DOI: 10.3928/01477447-20060701-08
16. Freund LG, Ovesen J Isolated dorsal dislocation of the radiocarpal joint. *J Bone Joint Surg Am* 1977, 59:277

17. Hardy P, Welby F, Stromboni M et al Wrist arthroscopy and dislocation of the radiocarpal joint without fracture. *Arthroscopy* 1999, 15:7:779-783
18. Howard RF, Slawski DP, Gilula LA Isolated palmar radiocarpal dislocation and ulnar translocation: a case report and review of the literature *J Hand Surg [Am]* 1997, 22:1:78-82
19. Jebson PJJ, Adams BD, Meletiou SD Ulnar translocation instability of the carpus after a dorsal radiocarpal dislocation; a case report. *Am J Orthop* 2000, 29:6:462-464
20. Matthews MG Radiocarpal dislocation with associated avulsion of the radial styloid and fracture of the shaft of the ulna. *Injury* 1987, 18:70-71
21. Moore DP, McMahan BA Anterior radio-carpal dislocation: an isolated injury. *J Hand Surg [Br]* 1988, 13:215-217
22. Penny WH III, Green TL Volar radiocarpal dislocation with ulnar translocation. *J Orthop Trauma* 1988, 2:322-326
23. Reynolds ISR Dorsal carpal dislocation. *Injury* 1980, 12:48-49
24. Tanzer TL, Horne JG Dorsal radiocarpal fracture dislocation. *J Trauma* 1980, 20:999-1000
25. Thomsen S, Falstie-Jensen S Palmar dislocation of the radiocarpal joint. *J Hand Surg [Am]* 1989, 14:627-630
26. Varodompun N, Limpivest P, Prinyaroj P Isolated dorsal radiocarpal dislocation: case report and literature review. *J Hand Surg [Am]* 1985, 10:708-710
27. Nyquist SR, Stern PJ Open radiocarpal fracture-dislocations. *J Hand Surg [Am]* 1984, 9:707-710
28. Mudgal CS, Psenica J, Jupiter JB Radiocarpal fracture-dislocation. *J Hand Surg [Br]* 1999, 24:92-98
29. Girard J, Cassagnaud X, Maynou C et al Radiocarpal dislocation: Twelve cases and a review of the literature. *Rev Chir Orthop* 2004, 90:426-433 DOI: 10.1016/s0035-1040(04)70169-5
30. Dumontier C, Meyer zu Reckendorf G, Sautet A et al Radiocarpal dislocations: Classification and proposal for treatment (a review of twenty-seven cases). *J Bone Joint Surg Am* 2001, 83:212-218 DOI: 10.2106/00004623-200102000-00008
31. Taleisnik J *The Wrist*. Churchill Livingstone, New York Edinburgh London Melbourne 1985
32. Kapandji IA Etude du carpe au scanner a trois dimensions sous contraintes de pronosupination. *Ann Chir Main* 1991, 10:36-47
33. Fernandez DL, Jupiter JB, Ghillani R Radiocarpal fracture-dislocation. In: Fernandez DL, Jupiter JB (eds) *Fractures of the distal radius. A practical approach to management*, ed 2. Springer, Ch 8, 2002, pp 253-264
34. Ilyas A, Mudgal C, Jupiter J Volar rim and Barton's fracture. In: Slutsky DJ, Osterman AL (eds) *Fractures and injuries to the distal radius and carpus*. Saunders Elsevier, ch 14, 2009, pp 157-163
35. Sivan M, Davies N, Archibald C et al An unusual combination of radiocarpal fracture dislocation, scaphoid fracture and posteromedial elbow dislocation. *Injury Extra* 2005, 36:312-315. DOI: 10.1016/j.injury.2004.12.057
36. Watanabe K, Nishikimi J Transstyloid radiocarpal dislocation. *Hand Surg* 2001, 6:1:113-120
37. Ilyas A, Mudgal C Radiocarpal Fracture-dislocations. *J Am Acad Orthop Surg* 2008,16:647- 655 DOI: 10.5435/00124635-200811000-00005
38. Graham TJ The inferior arc injury: an addition to the family of complex carpal fracture-dislocation patterns. *Am J Orthop* 2003, 32:9:10-19
39. Oberladstätter J, Arora R, Dallapozza C et al Radiological radio-carpal and mid-carpal motion after operative treatment of dorsal radio-carpal fracture dislocations. *Arch Orthop Trauma Surg* 2010, 130:77-81, DOI: 10.1007/s00402-009-0902-0
40. Cohen MS, McMurtry RY, Jupiter JB Fractures of the distal radius. In: Browner BD, Jupiter JB, Levine AM, Trafton PG (eds) *Skeletal Trauma*, ed 2. WB Saunders, 1998, Philadelphia, pp 1385
41. Fernandez DL, Jupiter JB Articular marginal shearing fractures. In: Fernandez DL, Jupiter JB (eds) *Fractures of the distal radius. A practical approach to management*, ed 2. Springer, Ch 6, 2002, pp 188-212
42. King RE Barton's enigma. *J Bone Joint Surg Am* 1959, 41:753-769
43. Lozano-Calderón SA, Doornberg J, Ring D Fractures of the dorsal articular margin of the distal part of the radius with dorsal radiocarpal subluxation. *J Bone Joint Surg Am* 2006, 88:7:1486-1493

- DOI: 10.2106/JBJS.E.00930
44. Idler RS Carpal dislocations and instability. In: Watson HK, Weinzweig J (eds) *The Wrist*, vol 1. Lippincott Williams & Wilkins, 2001, pp 203-229
 45. Weiss C, Laskin RS, Spinner M Irreducible radiocarpal dislocation. *J Bone Joint Surg Am* 1970, 52:562-564
 46. Stoffelen D, Fortems Y, De Smet L et al Dislocation of the distal radioulnar joint associated with a transstyloid radiocarpal fracture dislocation a case report and review of the literature. *Acta Orthop Belg* 199, 662:2:52-55
 47. Campbell DA Ulnar head and styloid fractures. In: Slutsky DJ, Osterman AL (eds) *Fractures and injuries to the distal radius and carpus. The cutting edge*. Saunders, Ch 28, 2009, pp 297-308
 48. Gabl M, Lener M, Pechlaner S Destabilization of the discus articularis with rupture of the ulnar styloid apex in distal radius fracture. Diagnosis with dynamic MR. *Unfallchirurgie* 1993, 19:108
 49. Lindau T, Adlercreutz C, Aspenberg P Peripheral tears of the triangular fibrocartilage complex cause distal radioulnar joint instability after distal radial fractures. *J Hand Surg [Am]* 2000, 25:3:464-468
 50. Souer JS, Ring D, Matschke S et al Effect of an unrepaired fracture of the ulnar styloid base on outcome after plate-and-screw fixation of a distal radial fracture. *J Bone Joint Surg Am* 2009, 91:4:830-838 DOI: 10.2106/JBJS.H.00345
 51. May MM, Lawton JN, Blazar PE Ulnar styloid fractures associated with distal radius fractures: incidence and implications for distal radioulnar joint instability. *J Hand Surg [Am]* 2002, 27:6:965-971 DOI: 10.1053/jhsu.2002.36525
 52. Bozentka DJ, Beredjiklian PK Classification of radiocarpal dislocations and appropriate treatment. *J Bone Joint Surg Am* 2001, 83:10:1587-1588
 53. Hofmeister EP, Fitzgerald BT, Thomson MA et al Surgical reconstruction of a late-presenting volar radiocarpal dislocation: a case report. *Am J Orthop* 2008, 37:2:96-99
 54. Takase K, Yamamoto K, Yoshino S et al Palmar dislocation of the radio-carpal joint: A case report. *J Orthop Surg* 2004, 12:2:258-262
 55. Antuna SA, Mendez JG, Paz Jimenez J Displaced radiocarpal dislocation with multiple associated fractures. *Acta Orthop Belg* 1994, 60:430-431
 56. Rosado AP A possible relationship of radiocarpal dislocation and dislocation of the lunate bone. *J Bone Joint Surg Am* 1966, 48:504-506
 57. Lourie JA An unusual dislocation of the lunate and the wrist. *J Trauma* 1982, 22:966-967
 58. Rayhack JM, Linscheid RL, Dobyns JH et al Post-traumatic ulnar translation of the carpus. *J Hand Surg [Am]* 1987, 12:180-189
 59. Lipton HA, Jupiter J Open reduction and internal fixation of distal radius fractures. In: Watson HK, Weinzweig J (eds) *The wrist*. Lippincott Williams & Wilkins, 2001 pp 333-335
 60. Fernandez DL, Jupiter JB Fracture of the distal end of the radius: A historical perspective. In: Fernandez DL, Jupiter JB (eds) *Fractures of the distal radius. A practical approach to management*, ed 2. Springer, 2002, Ch 1, pp 1-22
 61. Berger RA, Weiss AP *Hand Surgery*. Lippincott Williams & Wilkins, 2004
 62. Cooney WP, Linscheid RL, Dobyns JH *The Wrist. Diagnosis and operative treatment*. Mosby, Mayo Clinic Division of Hand Surgery 1998.
 63. Watson HK, Weinzweig J *The Wrist*. Lippincott Williams & Wilkins 2001
 64. Chin KR, Jupiter JB Wire-loop fixation of volar displaced osteochondral fractures of the distal radius. *J Hand Surg [Am]* 1999, 24:525-533
 65. Maschke S, Means KR, Parks BG et al A radiocarpal ligament reconstruction using brachioradialis for secondary ulnar translation of the carpus following radiocarpal dislocation: a cadaver study. *J Hand Surg [Am]* 2010, 35:2:256-261 DOI: 10.1016/j.jhsa.2009.10.011
 66. Obafemi A, Pency R Palmar radiocarpal dislocation: a case report and novel treatment method. *Hand* 2012, 7:114-118 DOI: 10.1007/s11552-011-9374-0
 67. Schweitzer G Radiocarpal fracture-dislocation [letter]. *Clin Orthop* 1987, 216:298-299
 68. Dobyns JH, Linscheid RL, Chao EYS et al Traumatic instability of the wrist. In: *AAOS Instructional Course Lectures Vol. 24*. CV Mosby: St Louis, 1975, pp 182-199

69. Kamal RN, Bariteau JT, Beutel BG et al Arthroscopic reduction and percutaneous pinning of a radiocarpal dislocation. A case report. *J Bone Joint Surg [Am]* 2011, 93:15:1-5 DOI: 10.2106/JBJS.J.01306
70. Berschback JC, Kalainov DM, Husain SN et al Traumatic ulnar translocation of the carpus: early recognition and treatment. *J Hand Surg [Eur]* 2012, 37:8:755-764 DOI: 10.1177/1753193412436626
71. Mulier T, Reynders P, Broos P et al Posttraumatic ulnar translation of the carpus. *Acta Orthop Scand* 1992, 63:1:102-103
72. Schernberg F Ulnar translation of the carpus: a rare type of wrist instability. In: Buchler U (ed) *Wrist instability*. Martin Dunitz 1996, Ch 23, pp 175-179
73. Garcia-Elias M Carpal instabilities and dislocations. In: Green DP, Hotchkiss RN, Pederson WC (eds) *Green's Operative Hand Surgery*, vol 1. Churchill Livingstone, New York, 1999, ch. 28, pp 865-928
74. Chamay A, Della Santa D, Vilaseca A Radiolunate arthrodesis. Factor of stability for the rheumatoid wrist. *Ann Chir Main* 1983, 2:5-17
75. DiBenedetto MR, Lubbers LM, Coleman CR A standardized measurement of ulnar carpal translocation. *J Hand Surg [Am]* 1990, 15:1009-1010
76. McMurtry RY, Youm Y, Flatt AE et al Kinematics of the wrist. II. Clinical applications. *J Bone Joint Surg Am* 1978, 60:955-961
77. Bouman HW, Messer E, Sennwald G Measurement of ulnar translation and carpal height. *J Hand Surg [Br]* 1994, 19:325-329
78. Gilula LA, Weeks PM Post-traumatic ligamentous instabilities of the wrist *Radiology* 1978, 129:641-651
79. Schuind FA, Linscheid RL, An KN et al A normal data base of posteroanterior roentgenographic measurements of the wrist. *J Bone Joint Surg Am* 1992, 74:1418-1429

READY - MADE
CITATION

Apergis E, Kyriakopoulos G, Bonatsos S, Maris S. Treatment of radiocarpal dislocations or fracture-dislocations based on a new classification scheme. *Acta Orthop Trauma Hell* 2020; 71(2): 47-62.

Vascularized bone grafting from the dorsal distal radius based on 4th extensor compartment artery for Kienböck's disease. Current concepts and a new surgical technique

Frantzeska Zampeli, MD, PhD, Emmanouil Fandridis MD, PhD, Sarantos Spyridonos, MD, PhD
Hand-Upper Limb-Microsurgery Department, General Hospital KAT, Athens, Greece

ABSTRACT

The optimal treatment option for Kienböck's disease is determined by the stage of the disease, ulnar variance, status of the lunate cartilage shell and presence of arthritic changes. The vascularized bone grafts are attractive treatment options for stage II and III according to Stahl-Lichtman classification. The purpose of this article is to present an overview for Kienböck's disease and describe our technique of the 4th extensor compartment artery vascularized bone graft for Kienböck's disease and its usefulness in the current concepts of treatment for Kienböck's disease.

KEY WORDS: Kienböck's disease, vascularized bone grafting, 4th extensor compartment artery

Introduction

Kienböck's disease, also known as idiopathic lunate osteonecrosis, has an etiology and pathogenesis that have not been absolutely determined even nowadays.

Interestingly regarding the historical background of the disease, it has been reported that even from 1843, before the advent of radiographs, Peste described collapse of the lunate bone in anatomic specimens and he attributed this finding to an acute, traumatic event. Later, Robert Kienböck an Austrian pioneer radiologist noted collapse and sclerosis of the lunate on radiographs and in 1910 he published the classic description in his publication "*Concerning traumatic malacia of the lunate and it's consequences*". He suggested "*distur-*

bance in the nutrition of the lunate caused by the rupture of the ligaments and blood vessels" after repeated trauma as most prominent etiology and he also described the natural history with carpal collapse leading to secondary arthritis [1].

Pathogenesis

Osseous and vascular anatomic variations are considered predominant causative factors for idiopathic lunate osteonecrosis as they render the lunate blood supply vulnerable to trauma (acute or repetitive).

The arterial blood supply to the lunate is mainly delivered to the non-articular portion of both its dorsal and palmar aspect by 3-5 vessels on average. Howev-

CORRESPONDING
AUTHOR,
GUARANTOR

Emmanouil Fandridis, Orthopaedic Surgeon
Hand-Upper Limb-Microsurgery Department, General Hospital KAT, Athens,
Greece
fandridis@hotmail.com

er, a 7% of specimens receives blood supply by a single palmar vessel. Also, in 30% of specimens there is limited intraosseous branching ("I," "X," or "Y" patterns have been described). Such lunate specimens with a single supply vessel or limited intraosseous branching are at increased risk for osteonecrosis [2]. Disruption of venous outflow has also been implicated in the etiology of Kienböck's disease [3]. Lunate morphology and variations in local osseous anatomy have also been theorized causative factors for lunate osteonecrosis. In cases with negative ulnar variance the increased height of the radius increases the force transmission across the radiolunate joint, predisposing to osteonecrosis [4]. Decreased radial inclination and a small size of lunate bone have both been implicated as factors in the development of Kienböck's disease, while recently, the trabecular microstructure of the lunate has also been examined [5]. The most pertinent interpretation is that the pathogenesis of Kienböck's disease is multifactorial and co-influenced by genetic, anatomic, mechanical, and metabolic factors [2].

Natural history

Idiopathic avascular lunate osteonecrosis is a progressive disorder and leads to a predictable pattern and continuum of pathologic changes from increased lunate radiodensity to lunate fragmentation, lunate collapse and finally progression to radiocarpal and midcarpal arthritis [6,7]. This is the natural history of Kienböck's disease if left untreated and it progresses throughout these stages over several years. However, while a predictable, progressively worsening pattern of lunate osteonecrosis occurs, clinical symptoms do not necessarily correlate with this pathoanatomic process. Each stage of the disease may be the first presentation of lunate osteonecrosis since not always all stages in every patient are painful [8]. The surgery's ability to alter the disease progression is also not well-defined [8,9].

Classification systems

Whereas several classification schemes have been suggested, the one that is most commonly used in the Stahl-Lichtman classification (the one developed by Lichtman et al after revisions on the system originally described by Stahl) [10]. At this scheme staging of

Kienböck's disease depends on the radiographic findings. Staging is an important step in the evaluation of a patient with Kienböck's disease because the surgical management options are largely affected by the stage of disease.

In stage I x-rays show normal density of the lunate with no sclerosis or collapse.

Magnetic resonance imaging may reveal diffuse decreased T1 signal. In stage II the lunate appears diffusely sclerotic on radiographs with no articular collapse or loss of lunate height. Fracture lines may appear. In stage III there is collapse of the articular surface. In stage IIIA carpal height and alignment remain normal, whereas in stage IIIB lunate collapse is accompanied by carpal instability, fixed scaphoid rotation, decreased carpal height and proximal capitate migration. In order to differentiate between stage IIIA and IIIB, a radioscapoid angle greater than 60° was introduced to define carpal instability and stage IIIB [11]. Finally, stage IV is characterized by lunate collapse and radiocarpal or midcarpal arthritis.

Stage IIIC was described later and includes a coronal fracture of the lunate. Due to poor clinical outcome it was suggested that a coronal lunate fracture, regardless of carpal stability, should be treated with a salvage procedure [12].

Bain et al used diagnostic arthroscopy and developed an articular-based classification system for Kienböck's disease. These authors suggested that treatment should be designed based on the findings of the articular cartilage pathology during wrist arthroscopy [13].

Treatment principles

The appropriate treatment strategy for Kienböck's disease depends on the Stahl-Lichtman stage, type of ulnar variance, coexistence of arthritic changes and whether the articular cartilaginous shell of the lunate is intact [14]. Besides, the clinical presentation of the patient should be considered because not seldom radiographic findings do not correlate with patient symptoms [8]. Therefore, although the radiographic stage directs treatment options, on the other hand the presence of abnormal x-ray findings alone does not necessarily mandate surgical intervention. Consequently, the need for treatment and the most appropriate treat-

ment option is dictated by thorough assessment of patient's characteristics, symptoms and their severity, functional deficits and the aforementioned radiological parameters and staging. Treatment options range from conservative measurements (immobilization) to surgical interventions.

Surgical treatment can be categorized into 3 broad categories:

Mechanical: aim to unload the lunate: joint leveling procedures (radial shortening/wedge osteotomy) [15-21], capitate shortening osteotomy that can be combined or not with vascularized bone graft (VBG) [22-25], arthroscopic core decompression of the lunate [26], and metaphyseal core decompression of the radius or ulna [27].

Biological: aim to revascularize the lunate: direct implantation of an arteriovenous pedicle [28-30], pisiform transfer [31], pronator quadratus pedicle flap [32], index metacarpal [33], pedicled dorsal distal radius [34], and revascularization with free iliac or medial femoral condyle bone grafting [35].

Salvage: wrist denervation, lunate excision [36], lunate replacement [37], proximal row carpectomy [38], limited [39, 40] or total wrist fusion [41], and total wrist arthroplasty.

Lunate revascularization

Lunate revascularization is performed by transferring vessels or vascularized autogenous tissue (free or pedicled) from a donor site to the necrotic lunate bone. Implantation of arteriovenous bundles (an artery and its venae comitantes) [28] or vascularized bone flaps (grafts, VBG) have been used in Kienböck's disease.

Revascularization and remodeling of surrounding avascular and necrotic bone is promoted and accelerated by a VBG. One of the advantages of VBG is that they act relatively independently of the recipient host bed as they are implanted with their own blood supply [42]. One of the main differences with non-vascularized grafts is that more than 90% of the osteocytes survive the transplantation procedure [43], and recipient site revascularization occurs much more rapidly because the bone resorption and creeping substitution of necrotic bone mechanisms that take place with non-vascularized grafts, do not occur with VBGs [43].

The lack of this resorption phase before revascularization results in superior and faster structural strength during the first six weeks after implantation when VBGs are used [42]. During this initial period these grafts still require mechanical stability while they incorporate into the host bed.

Revascularization procedures with VBG in the treatment of Kienböck's disease are suggested in cases that the lunate cartilage shell is intact (without fracture or fragmentation) and there is absence of carpal arthritis [44,45]. Under these circumstances, it is also ideal procedure in ulnar neutral or positive variance patients where radial shortening is contraindicated. One of the most important parameters for success of vascularized bone grafting in Kienböck's disease is to have a pedicle of sufficient length to reach the host site without excessive tension [46]. The VBG must have nutrient vessels supplying both cortical and cancellous bone and receive sufficient blood flow to maintain its viability and through this to promote revascularization of the recipient site, ie the necrotic lunate. With these principles strictly adhered to, a number of VBG based on a variety of pedicles from dorsal or palmar aspect of the wrist [31,34,47-52] have been devised in the treatment of Kienböck's disease with most important: (1) 4+5 extensor compartment artery (ECA) bone graft, (2) second or third metacarpal base bone grafts, (3) 2,3 intercompartmental supraretinacular (ICSRA) or 1,2 ICSRA bone grafts, (4) pisiform bone graft, (5) volar bone grafts from the distal radius, and also (6) free pedicle bone grafts from the medial femoral condyle and the iliac crest [29,30,32,35,45,53-57].

Vascular anatomy of dorsal distal radius

Several vascularized bone grafts that can be used to treat carpal pathology had already been described such as those from volar radius/pronator quadratus muscle-bone graft, from second metacarpal, and the pisiform. In 1994 in their landmark study for arterial blood supply of distal radius and ulna, Sheetz and colleagues identified several vascular pedicles and based on these, several novel reverse flow pedicled VBG from the dorsal distal radius that could serve as additional graft sources for the hand surgeon when treating Kienböck's disease [53]. These new graft sources had some advantages that made them promising and

attractive: the reliable nutrient vessel blood supply, the relative technical ease of harvest and single surgical incision for both harvest and implanting, and finally the long pedicle length.

The study of Sheetz et al showed that the arterial blood supply of dorsal distal radius is provided by four longitudinal vessels, it is robust and constant [53]. These constant longitudinally oriented arteries supply nutrient vessels to the dorsal distal radius and have consistent relationships to adjacent anatomic landmarks. Furthermore, three dorsal arterial arches provide significant anastomotic connections to these four longitudinal arteries, allowing each of them to serve as a distally based and retrograde-flow pedicle graft.

The posterior division of anterior interosseous artery and the radial artery are the primary sources of antegrade blood flow to the distal dorsal radius. Four arteries arise from them, supply the dorsal radius with nutrient branches, and give rise in the design of pedicle grafts. These four arteries are named according to their relationship with the extensor compartments and the extensor retinaculum. Two of them lie *superficially* to the extensor retinaculum, and are located between extensor tendon compartments giving nutrient branches to underlying bony tubercles between these compartments. These are the 1,2 and 2,3 intercompartmental suparetinacular arteries (1,2 ICSRA and 2,3 ICSRA), that they pass between 1st-2nd and 2nd-3rd extensor compartments respectively. The other two longitudinal arteries are deeper, and they lie within the floor of respective extensor compartments in the radial side of it, named the 4th and 5th extensor compartmental arteries (4th ECA and 5th ECA).

The 1,2 ICSRA is present in 94%, it is the smallest of the four vessels with mean internal diameter 0.3 mm and originates from the radial artery approximately 5 cm proximally to the radiocarpal joint. It runs beneath the brachioradialis muscle and lie on the extensor retinaculum before entering the anatomic snuffbox to anastomose with the radial artery and/or the radiocarpal arch. It is usually used as a graft to scaphoid due to its superficial location and limited arc of rotation.

The 2,3 ICSRA is present 100% of the time and originates from the anterior interosseous artery or the posterior division of the anterior interosseous artery. It lies

superficial to the extensor retinaculum, lies on Lister's tubercle and anastomoses with the dorsal intercarpal arch, the dorsal radiocarpal arch or the fourth ECA. It gives nutrient branches deep into cancellous bone and has similar mean internal diameter (0.35 mm) but greater arc of rotation than the 1,2 ICSRA, thus being appropriate graft source also for Kienböck's disease except from scaphoid nonunions.

The fourth ECA initiates from the posterior division of the anterior interosseous artery or its 5th extensor compartment branch and distally anastomoses with the dorsal radiocarpal and dorsal intercarpal arch. It lies on the radial aspect of the fourth extensor compartment and locates directly adjacent to the posterior interosseous nerve. It gives rise to numerous nutrient arteries to the distal dorsal radius that penetrate deeply into cancellous bone.

The fifth ECA originates from the posterior division of the anterior interosseous artery and is the largest of the four dorsal vessels (mean internal diameter 0.49 mm). It locates at the radial side of the floor of the fifth extensor compartment, it passes through the 4,5 septum and anastomoses with the dorsal radiocarpal arch, the dorsal intercarpal arch, the 2,3 ICSRA, the fourth ECA, and the oblique dorsal artery of the distal ulna. The advantages of the 5th ECA include its multiple anastomoses, its large diameter, the ulnar location that puts it away from capsulotomy incisions that are usually required to expose carpal bones and render it a desirable source of retrograde blood flow. On the contrary a relative disadvantage is that the fifth ECA seldom provides direct antegrade nutrient branches to the dorsal distal radius as compared to the other three dorsal arteries. For this reason, a respective VBG that is used is not a 5th ECA based VBG but rather a 4th +5th ECA VBG due to the proximal anastomosis or common origin with the 4th ECA.

A series of transverse arterial arches that locate distally to these compartmental and intercompartmental arteries and lie across the dorsum of the wrist, provide the distal anastomotic network for the ICSRA and ECA and give the retrograde blood flow for the respective VBGs. These include the dorsal intercarpal arch, the dorsal radiocarpal arch and the dorsal suparetinacular arch. The dorsal intercarpal arch is the most important than the others and anastomo-

ses with the 1,2 ICSRA, 2,3 ICSRA, the fourth ECA, and the dorsal radiocarpal arch thus being important and vital element of several potential grafts. On the other hand the dorsal radiocarpal arch has limited usefulness as a potential source of retrograde arterial flow due to its tendency to course deep to dorsal capsule and by its small caliber ulnarly which both make dissection difficult and adequate blood flow inconsistent.

All these characteristics of nutrient branches coming from the longitudinal vessels to the dorsal distal radius, and the distal anastomoses coming from the transverse arches allows to harvest relevant distally based or reverse flow VBG from the distal radius following proximal vessel ligation. The arc of rotation of each harvested VBG is a factor to take in consideration respecting their applicability.

Our surgical technique

In this article we present our surgical technique using a 4th ECA VBG for treatment of stage II and III (Stahl-Lichtmann classification) Kienböck's disease. In contrast to 4+5 ECA pedicle bone grafting that is considered the most reliable form of revascularization, the 4th ECA avoids the more extensive dissection and the higher risk of pedicle kinking due to the long pedicle of 4+5 ECA. On the other hand, special considerations regarding the capsulotomy are provided in order to secure the preservation of retrograde blood flow.

Indications

We use the 4th ECA VBG for stage II and for stage IIIA disease. Stage IIIB disease has been considered contraindication for vascularized bone grafting, however it is recently recommended that the most important factor in determining feasibility of vascularized bone grafting is the status of the articular cartilage shell of the lunate [1]. In our cases with an intact cartilage shell of the lunate and absence of marked arthritic changes, vascularized bone grafting from the 4th ECA is a viable option. In cases with ulna neutral or positive variance, in which joint leveling is contraindicated, VBG is also an appropriate method to revascularize the lunate. In ulna negative variance we use vascularized bone grafting as an adjunctive procedure to radial shortening.

Contra-indications

Contraindications for the procedure include stage IV disease and lunate fracture with fragmentation of the cartilage shell. Coronal fracture (IIIC) is also a relative contraindication although fixation with a screw in the acute setting has been proposed [45]. Previous surgery at the dorsal wrist through extensor retinaculum or wrist arthroscopy via the 4–5 portal are relative contraindications for using this graft, due to potential prior violation of the underlying 4th ECA vascular pedicle or the retrograde blood flow.

Surgical technique

Under axillary nerve block, the patient was placed in supine position, and pneumatic tourniquet is inflated at 250 mmHg of pressure after exsanguination has been performed from the wrist and proximally to enable visualization of the vessels during the operation.

If the status of lunate articular cartilage is under question, wrist arthroscopy can be performed to evaluate the lunate cartilage and the cartilage of the rest of the carpus, but the 4-5 portal and ulnar midcarpal portals are not used to prevent from possible damage to the 4th ECA and anastomotic branch from dorsal intercarpal arch.

A longitudinal dorsal wrist incision is made in line with the third metacarpal starting from its base and extending towards the distal forearm (**Fig 1**). Deep dissection is made with opening of the extensor retinaculum and creating two flaps to expose the fourth extensor compartment. The fourth ECA is located radially in the floor of the 4th compartment, radial to the posterior interosseous nerve (**Fig 2A**). It is traced and localized more proximally because later it will be ligated at this proximal site (**Fig 2B**) although it's not necessary to trace it up to its proximal origin from the posterior division of anterior interosseous artery.

After the localization of the fourth ECA, the approach to the dorsal surface of lunate bone is performed. At this stage before doing the capsulotomy it should be kept in mind that the blood flow on which the 4th ECA vascularized bone graft will be based is retrograde from the dorsal carpal arches, with the dorsal intercarpal arch (d ICA) being the most important [53]. With respect to this vascular anatomy that has been well-described, we propose a capsulotomy that

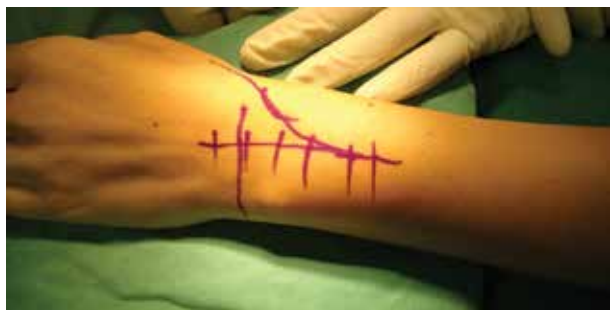

Figure 1. A standard longitudinal dorsal wrist incision is made in line with the third metacarpal starting from its base and extending towards distal forearm.

sparing the retrograde blood flow (Fig 3 and 4). The capsulotomy should be performed over the lunate and a capsular flap is created with its base ulnarly. This facilitates the visualization and exposure of lunate bone. Depending on the surgeon's preference, the somatometric characteristics of the patient and the location and extent of lunate necrosis, a rectangular or an angled-shape (or "L") capsulotomy are described (Fig 3, 4). The basic principle is to avoid compromising the anastomotic branch between the d ICA and the 4th ECA that is directly at the site of capsulotomy. The safest way to do it for both capsulotomies (rectangular and angled-shaped) is to perform the longitudinal cut centered over the lunate or slightly radially on the lunate but not too far radially in order to protect the anastomotic branch between the d ICA and the 4th ECA. In this way we create a flap that is ulnarly to the anastomotic branch (Fig 3A, 4A). However, since the d ICA and its anastomotic branch is located superficially to the capsule (in contrast to the dorsal radiocarpal arch that has the tendency to course deep to the dorsal capsule) [53] an alternative approach is to raise an ulnar based flap with the longitudinal cut more radially than the anastomotic branch (this offers much more visualization of the lunate) but only in the case we visualize the anastomotic branch that lies superficially on the capsule. In this case we raise a flap and the anastomotic branch is also raised with it on its superior surface (Fig 3B, 4B, 5, 7). The extension of the transverse limbs of our flap ulnarly (Fig 3C, 4C) as well as the extension of the longitudinal cut distally (i.e. how wide the flap will be in proximal-distal dimension) (Fig 3D, 4D) although they should be avoided when possible,

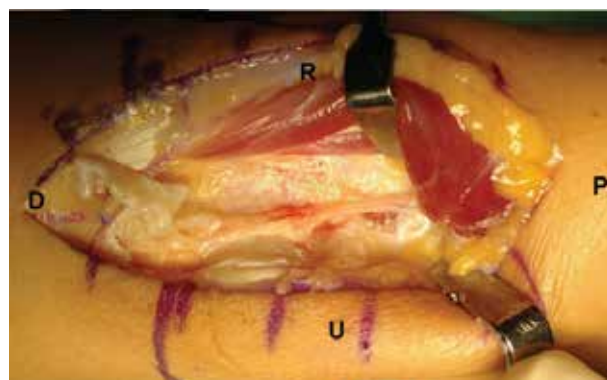
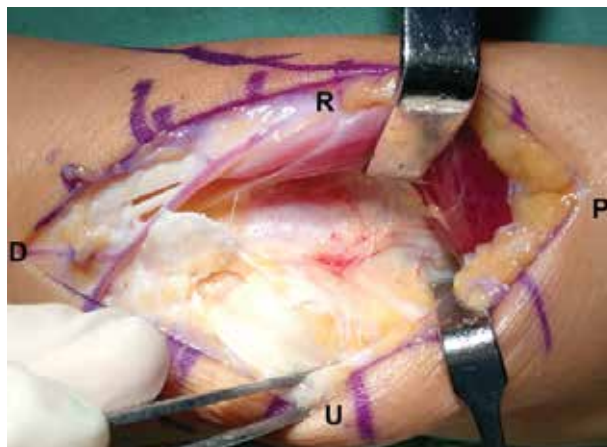


Figure 2. A. The fourth ECA and venae comitantes are visualized on the radial aspect of the floor of the 4th compartment, lying radially to the posterior interosseous nerve
B. The fourth ECA is traced and localized more proximally because later it will be ligated at this proximal site although it's not necessary to trace it up to its proximal origin from the posterior division of anterior interosseous artery. (R, radially; U, ulnarly; P, proximally; D, distally)

however, they do not put in risk the viability of the VBG since the retrograde blood flow follows the pathway from radial artery to the d ICA and from this to the 4th ECA (the radial half of the d ICA) [53]. This risk of extending the transverse limbs more to gain visualization could be fatal for a radially based flap, and this is one of the reasons that we do not recommend a radially based capsular flap. Other reason that a radially based flap should be avoided and not recommended is that it requires a cut to the ulnar side (since the base would be on radial side), which possibly affect part of the dorsal radiocarpal ligament.

After the capsulotomy has been completed the lu-

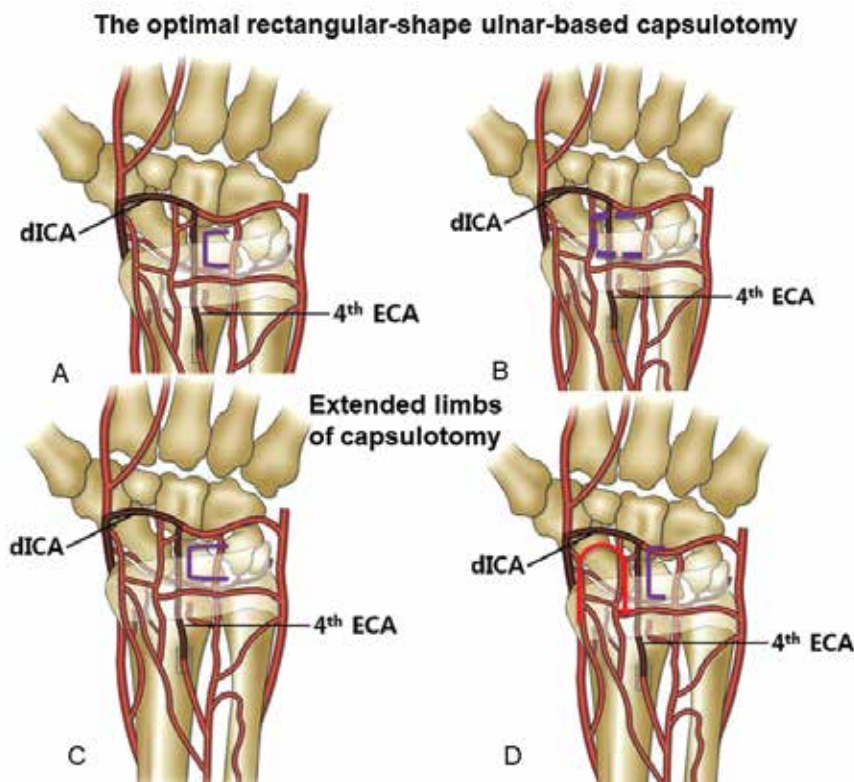


Figure 3. The aim of capsulotomy is to protect the dorsal intercarpal arch (dICA) that is located across the proximal border of the distal carpal row and the anastomotic branch that allows retrograde blood flow from the dICA to the 4th extensor compartmental artery (ECA) and thus to the vascularized bone graft that receives nutrient branches from the 4th ECA. The main path for this “network of retrograde blood flow” that will keep the VBG “alive” as shown in the anatomic study by Sheetz et al is the dark red pathway coming from the radial artery, through the d ICA and finally to the 4th ECA.

- A. Knowing this arterial blood anatomy, the capsular flap can be one of the following a rectangular-shaped and ulnar-based flap. Ideally the longitudinal cut is at the center of lunate or at the radial lip of it but not far radially to protect the anastomotic branch between the d ICA and the 4th ECA, so the longitudinal cut and the whole flap remains ulnarly to the anastomotic branch protecting it.
- B. The advantage of the d ICA and its anastomotic branch compared to the dorsal radiocarpal arch is that the former lies more superficially to the capsule whereas the latter tends to course deep to the capsule. Therefore in cases we can control and visualize the route of the anastomotic branch we can raise carefully the flap including on its superficial surface the anastomotic branch. In this case the longitudinal cut can be performed more radially “including” in our capsular flap the anastomotic branch.
- C. Due to the very limited space available when such capsulotomy is performed, the extension of the limbs of capsulotomy (either longitudinal or transverse limbs of the cut) may be extended from the surgeon to allow lunate visualization. In the ulnar-based flap this may be forgiving due to the specific “pathway of retrograde blood flow” shown by Sheetz et al. If the transverse cuts extend far ulnarly this may not sacrifice the retrograde blood flow, since the anastomotic branch is radially.
- D. Similarly, in some cases the flap may be wider (large longitudinal cut in the proximo-distal direction) to allow visibility accordingly to the extent of lunate necrosis. Although this should be avoided as it has the risk to cut the d ICA if this is not clearly seen, the blood flow will again be preserved for the VBG through the radial half of the d ICA that is the main “pathway” for the reverse blood flow (red arrow).

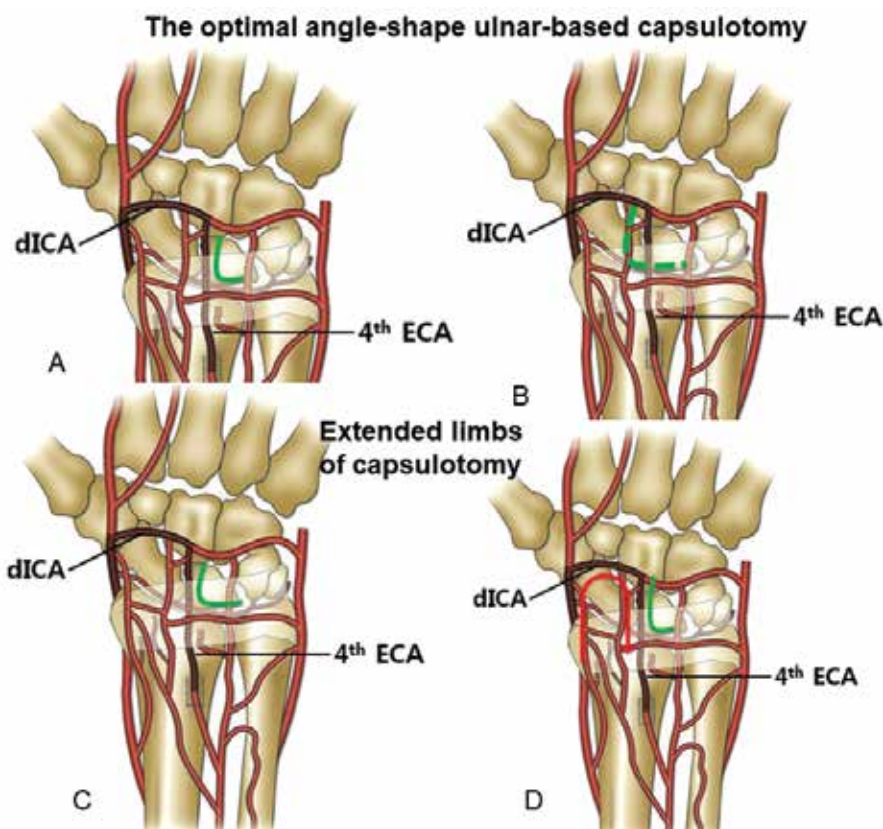


Figure 4. Similarly, the same principles for the retrograde blood flow and for the optimal capsulotomy (A) apply for an angle (“L”) shape ulnar-based capsulotomy flap. The choice of a rectangular or an angle shape capsulotomy depends on the surgeon’s preference, the somatometric of the patient (rectangular shape can be easier performed in larger wrists) and the extent and localization and the lunate necrosis. Again, an optimal (A) capsulotomy is described, but also one with longitudinal cut more radially than the anastomotic branch in cases we can visualize this vessel, protect it, and raise it with the flap. In cases that the limbs of capsulotomy extend more ulnarly (C) and more distally (D) depending on the intraoperative need for visualization, this may not disturb the pathway of retrograde blood flow.

nate is inspected (**Fig 5**) to examine the cartilage shell especially if arthroscopy was not performed at the beginning of the operation. If the cartilage shell is intact, without fragmentation and without arthritic changes, we proceed with the VBG. The necrotic bone tissue of the lunate is removed through a dorsal window using a burr and curette under direct visualization, while also fluoroscopic image may also be used to facilitate this step. (**Fig 6A,B**). At this stage we proceed to the scaphocapitate pinning (using two K-wires that will be kept for 6-8 weeks) to unload the lunate.

As next step, the bone graft is raised. The graft is centered approximately 10-11mm proximally to the radiocarpal joint overlying the 4th ECA because at this point the graft includes most of the nutrient vessels

[53]. The size of the graft should coincide the dimensions of the excavated area of the lunate that will be filled (**Fig 7A**). The 4th ECA is ligated proximally and the graft is elevated with sharp osteotomes (**Fig 7B**).

At this point release of the tourniquet is required to confirm the viability of the graft through the retrograde blood flow. Then the graft is implanted in a press fit manner in the lunate cavity (**Fig 8**). If necessary cancellous bone graft can be inserted into the lunate to fill an excessive void prior to graft insertion.

The wrist capsule is slightly repaired avoiding using too many sutures both to avoid postoperative stiffness and also to minimize the risk to struggle the pedicle. The flap of extensor retinaculum is replaced, and a long-arm postoperative hand splint is applied.

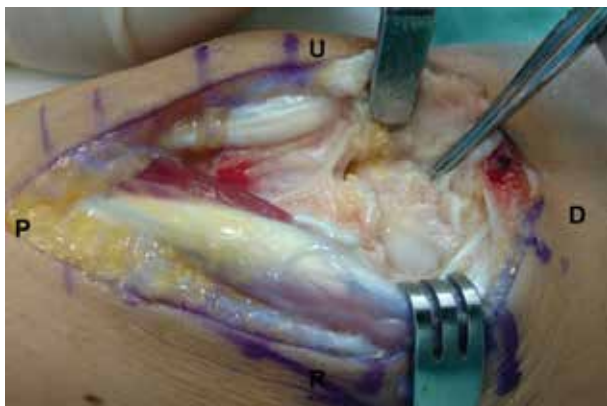


Figure 5. A rectangular-shaped ulnar-based capsulotomy with longitudinal cut more radially than the anastomotic branch according to pattern described in fig 3B has been performed (left wrist) and the lunate is inspected directly below.
(R, radially; U, ulnarly; P, proximally; D, distally)

Results

The radiologic outcome of the patient with stage II Kienböck's disease that is presented in this surgical technique paper is shown at **Figure 9**. Revascularization of the lunate is evident on magnetic resonance imaging with intravenous contrast agent. The patient showed improvement of pain and Mayo wrist score, as well as grip strength (from 60 to 80% of unaffected side) and wrist range of motion (from 70 to 90% of unaffected side) at 15 months follow up.

Revascularization techniques have shown promising results for Kienböck's disease. Even among different VBG sources from the dorsal wrist and hand, functional outcomes, pain relief, and improvement in range of motion are favorable and comparable [1,34,57,58]. The good clinical results may be preserved for some patients even though radiographic progression of lunate and carpal height collapse have been reported after VBG in 0-15% of patients [45].

A detailed understanding of the vascular anatomy of the dorsal distal radius allows the surgeon to raise VBG for treating Kienböck's disease. The use of 4+5 ECA vascularized bone graft was introduced by Moran et al to promote revascularization and remodeling of the necrotic lunate and is now the most commonly proposed and used method for lunate revascularization in Kienböck's disease when indicated [34]. This

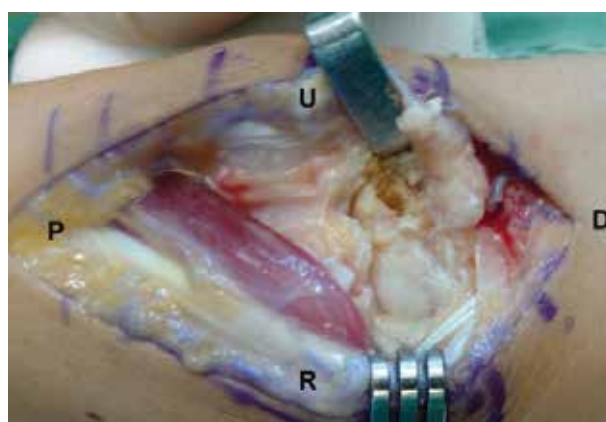
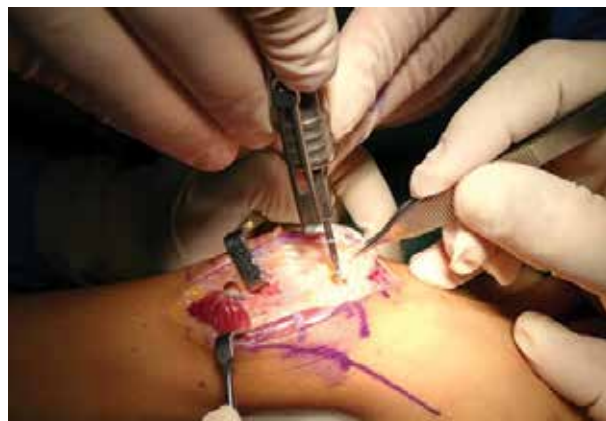

Figure 6. A, B Necrotic bone tissue of the lunate is removed through a dorsal window using a burr under direct visualization. Fluoroscopic image may also be used.
(R, radially; U, ulnarly; P, proximally; D, distally)

technique requires ligation of the posterior branch of the anterior interosseous artery. The retrograde flow from the fifth ECA is then directed into the fourth ECA in an orthograde direction. In this way the pedicle that is used is of large diameter and pretty long to assess the host site, while its ulnar location in the wrist allows capsulotomy to be performed without any risk to injure necessary vessels [34,59,60]. However, we realized some shortcomings when performing this technique as also reported in the literature [61]: the time required for surgical dissection is relatively long, while the longer pedicle sometimes has the risk of kinking. Although comparison of different dorsal distal radius VBG sources for treatment of Kienböck's is limited and we do not know from any comparative study if these differ in their subjective and objective outcome measures, however we have noted that some of these

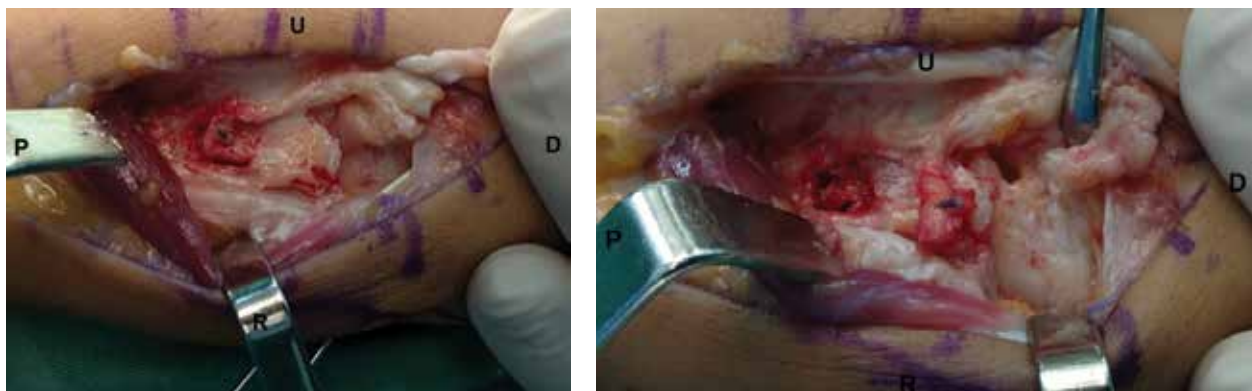


Figure 7.

- A. The graft is centered approximately 10-11mm proximally to the radiocarpal joint overlying the 4th ECA because at this point the graft includes most of the nutrient vessels (Sheetz). The size of the graft should coincide the dimensions of the excavated area of the lunate that will be filled.
- B. The 4th ECA is ligated proximally and the graft elevation is completed with sharp osteotomes. The pattern 3B of capsulotomy can be seen, and the anastomotic branch that provides the retrograde blood flow from d ICA to the VBG is seen on the superior aspect of the capsular flap.
- (R, radially; U, ulnarly; P, proximally; D, distally)

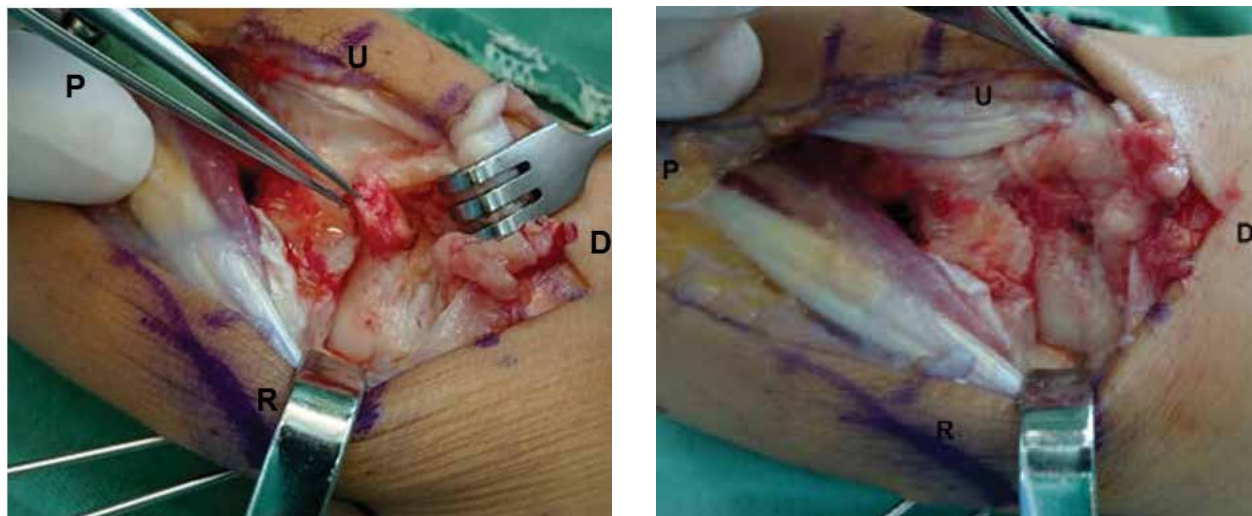


Figure 8. The graft is implanted in a press fit manner in the lunate cavity.

- A. A necessary turn is required and this is a possible weak point in the technique. The proximity of the pedicle to the final host site may balance this risk. However, we try to avoid more pressure on the pedicle by avoiding closing this part of the capsular flap at the end.
- B. The VBG in its final position in the lunate bone.
- (R, radially; U, ulnarly; P, proximally; D, distally)

challenges that may arise from the use of 4+5 ECA may be eliminated by use of the 4th ECA.

We showed that the fourth ECA technique may present some challenges regarding the capsulotomy

and requires a good understanding of the vascular anatomy that provides the retrograde arterial flow to the graft that is raised from the dorsal distal radius. According to this regional anatomy [53] we propose

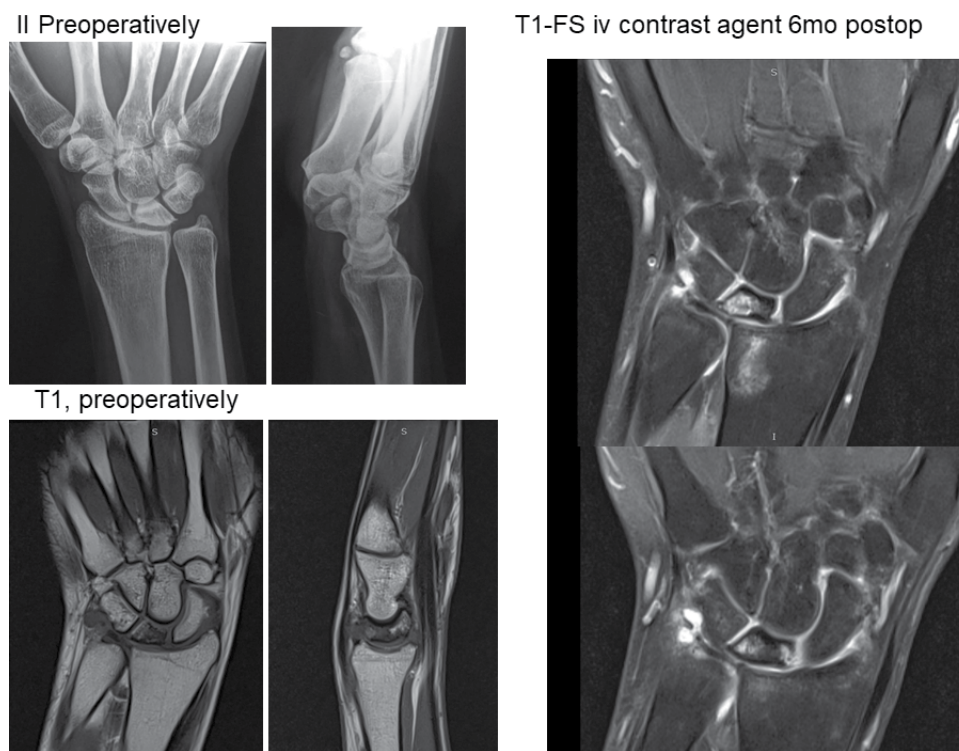


Figure 9. The radiologic outcome of the patient with stage II Kienböck's disease presented in this surgical technique paper is shown. Revascularization of the lunate is evident on magnetic resonance imaging with intravenous contrast agent 6 months postoperatively. No progression of the disease is noted.

the types of capsulotomy that spare this anastomotic branch, and they can be selected and performed in conjunction with other factors as the patient's somatometric characteristics, the surgeon preference and experience, and the capability to assess the lunate through a rectangular or angled-shaped capsular window in each case. Further clinical long-term results may reveal if the use of 4th ECA is a viable alternative to the 4+5 ECA VBG.

Conclusions

The surgical technique of the 4th ECA vascularized

bone grafting for Kienböck's disease is presented. Careful patient selection according to indications and meticulous and precise surgical technique may deteriorate the progression of disease and allow for revascularization of the necrotic lunate. The technique does not prevent from using another treatment option in the future if the disease progresses. Further clinical results are required to evaluate this technique in the long term. ^A

Conflict of interest

The authors declared no conflicts of interest.

REFERENCES

1. Derby BM, Murray PN, Shin AY, Bueno RA, Mathoulin CL, Ade T, Neumeister MW. Vascularized Bone Grafts for the Treatment of Carpal Bone Pathology. *Hand (NY)*. 2013;8(1):27-40
2. Lutsky K, Beredjiklian PK. Kienböck disease. *J Hand Surg Am* 2012;37(9):1942-1952
3. Schiltenswolf M, Martini AK, Mau HC, Eversheim S, Brocai DR, Jensen CH. Further investigations of the intraosseous pressure characteristics in necrotic lunates (Kienböck's disease). *J Hand Surg* 1996;21A:754-758.
4. Goeminne S, Degreef I, De Smet L. Negative ulnar variance has prognostic value in progression of Kienböck's disease. *Acta Orthop Belg* 76:38-41
5. Han KJ, Kim JY, Chung NS, Lee HR, Lee YS. Trabecular microstructure of the human lunate in Kienböck's disease. *J Hand Surg* 2012;37E:336-341.
6. Kristensen SS, Thomassen E, Christensen F. Kienböck's disease—late results by non-surgical treatment. A follow-up study. *J Hand Surg* 1986;11B:422-425.
7. Beckenbaugh RD, Shives TC, Dobyns JH, Linscheid RL. Kienböck's disease: the natural history of Kienböck's disease and consideration of lunate fractures. *Clin Orthop* 1980;Jun(149):98-106
8. Delaere O, Dury M, Molderez A, et al. Conservative versus operative treatment for Kienböck's disease: a retrospective study. *J Hand Surg Br*. 1998;23B:33-6
9. Dias J, Lunn P. Ten questions on kienböck's disease of the lunate. *J Hand Surg Eur*. 2010;35B:538-43.
10. Lichtman DM, Lesley NE, Simmons SP. The classification and treatment of Kienböck's disease: the state of the art and a look at the future. *J Hand Surg* 2010;35E:549-554.
11. Goldfarb CA, Hsu J, Gelberman RH, Boyer MI. The Lichtman classification for Kienböck's disease: an assessment of reliability. *J Hand Surg* 2003;28A:74-80.
12. Saunders B, Lichtman D. A classification-based treatment algorithm for Kienböck's disease: current and future considerations. *Tech Hand Up Extrem Surg*. 2011;15:38-40.
13. Bain G, Durrant A. An articular-based approach to Kienböck avascular necrosis of the lunate. *Tech Hand Up Extrem Surg*. 2011;15(1):41-7.
14. Shin AY, Bishop AT. Vascularized bone grafts for scaphoid nonunions and Kienböck's disease. *Orthop Clin North Am* 2001;32:263-277
15. Calfee R, Van Steyn M, Gyuricza C, et al. Joint leveling for advanced Kienböck's disease. *J Hand Surg Am*. 2010;35A:1947-54
16. Nakamura R, Nakao E, Nishizuka T, et al. Radial osteotomy for Kienböck's disease. *Tech Hand Up Extrem Surg*. 2011;15(1):48-54.
17. Nakamura R, Tsuge S, Watanabe K, et al. Radial wedge osteotomy for Kienböck disease. *J Bone Joint Surg Am*. 1991;73A(9):1391-6.
18. Salmon J, Stanley J, Trail I. Kienböck's disease: conservative management versus radial shortening. *J Bone Joint Surg Br*. 2000;82B:820-3.
19. Weiss A, Weiland A, Moore J, et al. Radial shortening for Kienböck disease. *J Bone Joint Surg Am*. 1991;73A(3):384-91.
20. Takahara M, Watanabe T, Tsuchida H, Yamahara S, Kikuchi N, Ogino T. Long-term follow-up of radial shortening osteotomy for Kienböck disease. Surgical technique. *J Bone Joint Surg Am* 2009;91(Suppl 2):184-190
21. Quenzer DE, Dobyns JH, Linscheid RL, Trail IA, Vidal MA. Radial recession osteotomy for Kienböck's disease. *J Hand Surg Am* 1997;22(3):386-395
22. Waitayawinyu T, Chin S, Luria S, et al. Capitate shortening osteotomy with vascularized bone grafting for the treatment of Kienböck's disease in the ulnar positive wrist. *J Hand Surg Am*. 2008;33A:1267-73.
23. Viola R, Kiser P, Bach A, et al. Biomechanical analysis of capitate shortening with capitate hamate fusion in the treatment of Kienböck's disease. *J Hand Surg Am*. 1998;23A:395-401.
24. Almquist E. Capitate shortening in the treatment of Kienböck's disease. *Hand Clin*. 1993;9:505-12.

REFERENCES

25. Gay A, Parratte S, Glard Y, et al. Isolated capitate shortening osteotomy for the early stage of Kienböck disease with neutral ulnar variance. *Plast Reconstr Surg*. 2009;124:560-6.
26. Bain G, Smith M, Watts A. Arthroscopic core decompression of the lunate in early stage Kienböck disease of the lunate. *Tech Hand Up Extrem Surg*. 2011;15(1):66-9.
27. Illarramendi A, De Carli P. Radius decompression for treatment of Kienböck disease. *Tech Hand Up Extrem Surg*. 2003;7 (3):110-3.
28. Hori Y, Tamai S. Blood vessel transplantation to bone. *J Hand Surg Am*. 1979;4A:23-33.
29. Simmons S, Tobias B, Lichtman D. Lunate revascularization with artery implantation and bone grafting. *J Hand Surg Am*. 2009;34A:155-60.
30. Tamai S. Bone revascularization by vessel implantation for the treatment of Kienböck's disease. *Tech Hand Up Extrem Surg*. 1999;3(3):154-61
31. Daecke W, Lorenz S, Wieloch P, et al. Vascularized os pisiform for reinforcement of the lunate in Kienböck's disease: an average of 12 years of follow-up study. *J Hand Surg Am*. 2005;30A:915-22.
32. Mathoulin C, Wahegaonkar A. Revascularization of the lunate by a volar vascularized bone graft and an osteotomy of the radius in treatment of the Kienböck's disease. *Microsurgery*. 2009;29:373-8.
- 33.
34. Bengoechea-Beeby M, Cepeda-Una J, Avascal-Zuloaga A. Vascularized bone graft from the index metacarpal for Kienböck's disease: a case report. *J Hand Surg Am*. 2001;26A:437-43.
35. Moran S, Cooney W, Berger R, et al. The use of the 4+5 extensor compartmental vascularized bone graft for the treatment of Kienböck's disease. *J Hand Surg Am*. 2005;30A:50-8.
36. Gabl M, Lutz M, Reinhart C, et al. Stage 3 Kienböck's: reconstruction of the fractured lunate using a free vascularized iliac bone graft and external fixation. *J Hand Surg Br*. 2002;27B:369-73.
37. Sakai A, Toba N, Oshige T, et al. Kienböck disease treated by excisional arthroplasty with a palmaris longus tendon ball: a comparative study of cases with or without bone core. *Hand Surg*. 2004;9(2):145-9.
38. Kawai H, Yamamoto K, Yamamoto T, et al. Excision of the lunate in Kienböck's disease. Results after long-term follow-up. *J Bone Joint Surg Br*. 1988;70B(2):287-92.
39. Nakamura R, Horii E, Watanabe K, et al. Proximal row carpectomy versus limited wrist arthrodesis for advanced Kienböck's disease. *J Hand Surg Br*. 1998;23B:741-5.
40. Tambe A, Ali F, Trail I, et al. Is radiolunate fusion a viable option in advanced Kienböck disease? *Acta Orthop Belg*. 2007;73:598-603.
41. Yasuda M, Masada K, Takeuchi E, et al. Scapho-trapezotrapezoid arthrodesis for the treatment of man stage 3B Kienböck disease. *Scand J Plast Reconstr Surg Hand Surg*. 2005;39:242-6.
42. Lin H, Stern P. "Salvage" procedures in the treatment of Kienböck's disease: proximal row carpectomy and total wrist arthrodesis. *Hand Clin*. 1993;9:521-6.
43. Dell PC, Burchardt H, Glowczewskie Jr FP. A roentgenographic, biomechanical and histological evaluation of vascularized and non-vascularized segmental fibula canine autografts. *J Bone Joint Surg Am* 1985;67(1):105-12.
44. Goldberg VM, Shaffer JW, Field G, et al. Biology of vascularized bone grafts. *Orthop Clin North Am* 1987;18(2):179-85.
45. Rizzo M, Moran SL. Vascularized bone grafts and their applications in the treatment of carpal pathology. *Semin Plast Surg* 2008;22(3):213-227
46. Elhassan BT, Shin AY. Vascularized bone grafting for treatment of Kienböck's disease. *J Hand Surg [Am]* 2009;34(1):146-54.
47. Cooley BC, Gould JS. The effect of venous flow alterations upon patency of rat femoral vein anastomoses. *Microsurgery* 1992;13(3):138-42.
48. Chacha PB. Vascularised pedicular bone grafts. *Int Orthop* 1984;8:117-138
49. Afshar A, Eivaziatashbeik K. Long-term clinical

REFERENCES

- and radiological outcomes of radial shortening osteotomy and vascularized bone graft in Kienböck disease. *J Hand Surg Am* 2013;38(2):289-296
50. Makino M. Vascularized metacarpal bone graft for scaphoid nonunion and Kienböck's disease. *J Reconstr Microsurg* 2000;16(4): 261-266
51. Bermel C, Saalabian AA, Horch RE, et al. Vascularization of the dorsal base of the second metacarpal bone: an anatomical study using C-arm cone beam computed tomography. *Plast Reconstr Surg* 2014;134(1):72e-80e
52. Saffar P. Replacement of the semilunar bone by the pisiform. Description of a new technique for the treatment of Kienböck's disease [in French]. *Ann Chir Main* 1982;1(3):276-279
53. Kuhlmann JN, Mimoun M, Boabighi A, Baux S. Vascularized bone graft pedicled on the volar carpal artery for non-union of the scaphoid. *J Hand Surg [Br]* 1987;12(2):203-210
54. Sheetz KK, Bishop AT, Berger RA. The arterial blood supply of the distal radius and ulna and its potential use in vascularized pedicle bone grafts. *J Hand Surg* 1995;20A:902-914.
55. Doi K, Oda T, Soo-Heong T, Nanda V. Free vascularized bone graft for nonunion of the scaphoid. *J Hand Surg* 2000;25A:507-519.
56. Fujiwara H, Oda R, Morisaki S, Ikoma K, Kubo T. Long-term results of vascularized bone graft for stage III Kienböck disease. *J Hand Surg Am* 2013;38(5):904-908
57. Hermans S, Degreef I, De Smet L. Vascularised bone graft for Kienböck disease: preliminary results. *Scand J Plast Reconstr Surg Hand Surg* 2007;41(2):77-81
58. Kakar S, Giuffre JL, Shin AY. Revascularization procedures for Kienböck disease. *Tech Hand Up Extrem Surg* 2011;15(1):55-6
59. Nakagawa M, Omokawa S, Kira T, Kawamura K, Tanaka Y. Vascularized bone grafts from the dorsal wrist for the treatment of Kienböck disease. *J Wrist Surg* 2016;5(2):98-104
60. Cheon SJ, Lim JM, Kim HT, Suh JT. Treatment of Kienböck's disease using the 4p5 extensor compartmental vascularized bone grafting procedure: early experience. *J Korean Orthop Assoc* 2010;45:256e63
61. Chung US, Kim KC, Lee KH. 4p5 extensor compartmental vascularized bone graft for stage III Kienböck's disease: preliminary results. *J Korean Soc Surg Hand* 2009;14:6e11
62. Park IJ, Kim HM, Lee JY, Roh YT, Kim DY, Jeon NH, Kim YD, Kang SH. Treatment of Kienböck's Disease Using a Fourth Extensor Compartmental Artery as a Vascularized Pedicle Bone Graft. *J Plast Reconstr Aesthet Surg*. 2016;69(10):1403-10

READY - MADE
CITATION

Zampeli F, Fandridis E, Spyridonos S. Vascularized bone grafting from the dorsal distal radius based on 4th extensor compartment artery for Kienböck's disease. Current concepts and ou surgical technique. *Acta Orthop Trauma Hell* 2020; 71(2): 63-76.

Kienböck disease, current issues

Pantelis K. Mitsikostas^{1,4}, Sofia A. Syngouna^{2,4}, Ioannis D. Aifantis^{3,4}, Ioannis S. Palavos^{1,4},
Sarantis G. Spyridonos⁴, Filippos S. Giannoulis⁴

¹1st Orthopaedic Department, KAT Hospital, Kifisia, Greece

²3rd Orthopaedic Department, University of Athens, KAT Hospital, Kifisia, Greece

³2nd Orthopaedic Department, KAT Hospital, Kifisia, Greece

⁴Hand-Upper Limb & Microsurgery Department, KAT Hospital, Kifisia, Greece

ABSTRACT

Kienböck's disease (KD) is a progressive condition leading to lunate collapse and carpal functionality disorder, with still uncertain etiology. The disease seems initially to affect the vascularity, lately the bone density and finally the cartilage of lunate. Advanced imaging and wrist arthroscopy offer useful tools for its approach. Classification, staging, therapeutic treatment and prognosis mostly depend on their findings. The cure algorithms that are usually followed include load redistribution, revascularization and lunate or wrist reconstruction as salvage surgery. Despite the great variation of operative options the majority of them provide satisfactory results.

KEY WORDS: Kienbock disease, lunate, wrist

Introduction

Kienböck's disease (KD) was initially described in 1910 by the Austrian radiologist Robert Kienböck (1871 - 1953). Although originally characterized as traumatic softening of the lunate, it is now defined as sedimentation of the whole lunate or part of it, with progressive evolution. The exact cause is not clearly clarified despite the fact that various pathophysiological mechanisms have been proposed. The lunate is the middle bone of the proximal row carpal bones and is articulated with scaphoid (lateral), capitate (distal), triquetrum (medial), hamate (distal and medial), radius and with the triangular fibrocartilage complex attached to the distal ulna. It is cres-

cent-shaped with a distal concave articular facet and a proximal convex articular facet. Load distribution between the forearm and the carpus is shared in the scaphoid and the lunate playing a crucial role as far as the function of the carpal is concerned.

Epidemiology

Kienböck disease is a rare condition with incidence < 5/10000 in general population but is a common type of avascular necrosis of the carpal bones (1). The characteristically affected population is young, males, aged 15 - 40 years old with unilateral symptoms. No difference between dominant and non-dominant hand seems to occur. Several cases of

CORRESPONDING
AUTHOR,
GUARANTOR

Filippos S. Giannoulis MD, PhD
Orthopaedic Surgeon, email: giannoulisfilippos@yahoo.gr

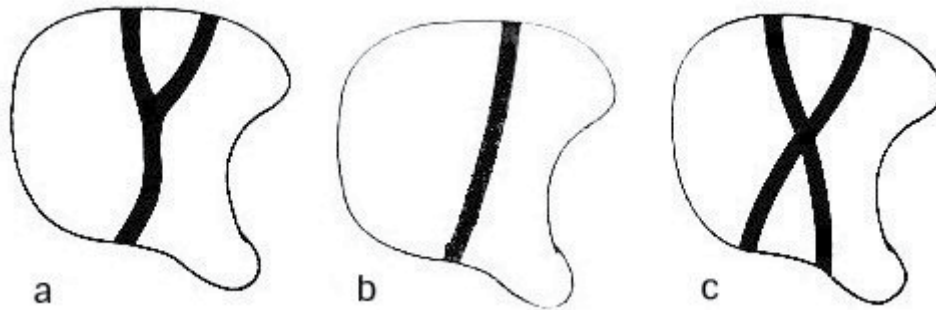


Figure 1. Normal lunate vascularity: a. pattern "Y", b. pattern "I", c. pattern "X"

Kienböck disease have been described in children where the disease is classified infantile (<12 yo) and juvenile (>12 yo) and in elder patients (2). Among carpal bones is the most common type of avascular necrosis.

Predisposing factors

In literature there is not a clear explanation for the exact cause of KD. Many pathophysiological pathways have been proposed in order to explain the trigger point and the progressive evolution of this condition.

The anatomy of the carpal has been initially implicated. A more radially inclined lunate tilting angle and a flatter radial inclination with or without the combination of a smaller lunate diameter and height seems to play a predisposing role (3). Patients with KD tend to present negative ulnar variance (incidence 3,1:1) in comparison to patients with neutral or positive ulnar variance (4). Blood supply is based in a complex of extraosseous and intraosseous vascular anastomosis arising from the radial, ulnar, and anterior interosseous artery. Three major intraosseous vascular patterns (**Fig.1**) have been described represented with the symbols Y, I, and X in frequency of occurrence (5). High intraosseous pressure, venous congestion and insufficient vascularity have been proposed as risk factors (5, 6). Joint motion can interfere negatively to blood flow of the lunate bone (7).

Great part of these patients (~ 70%) has a medical record of recent trauma or fracture, while the theory of repeated microtrauma has been proposed to

explain the common presence of the disease among labor workers and athletes.

Higher incidence of this condition is observed in patients with cerebral palsy, scleroderma, systemic lupus erythematosus, rheumatoid arthritis, dermatomyositis and Crohn's disease. A possible etiology of this correlation may come from the higher levels of antiphospholipid antibodies that are detected in Kienböck disease. Cases of concurrent avascular necrosis of other neighbor carpal bones may indicate a regional identity of the disorder (8).

Some authors propose the theory that this condition is rather a phenomenon that osteoclast prevails over osteoblast activity, during the procedure of reconstruction of microfractures. According to this hypothesis load disposition in the area seems to exacerbate and worsen the symptoms of an underlying situation (9).

Clinical presentation

Patients usually present unilateral carpal pain, located dorsally above lunate with restricted range of motion and various lack of strength. Symptomatology may deteriorate with axial loading during dorsal extension of the wrist. Medical history may reveal recent or former injury but it is not always a precondition.

In many cases the disease is possible to exist without symptoms or any other indications and be discovered as a random finding in radiological examination.

Classification

Lichtman classification, that is the most common

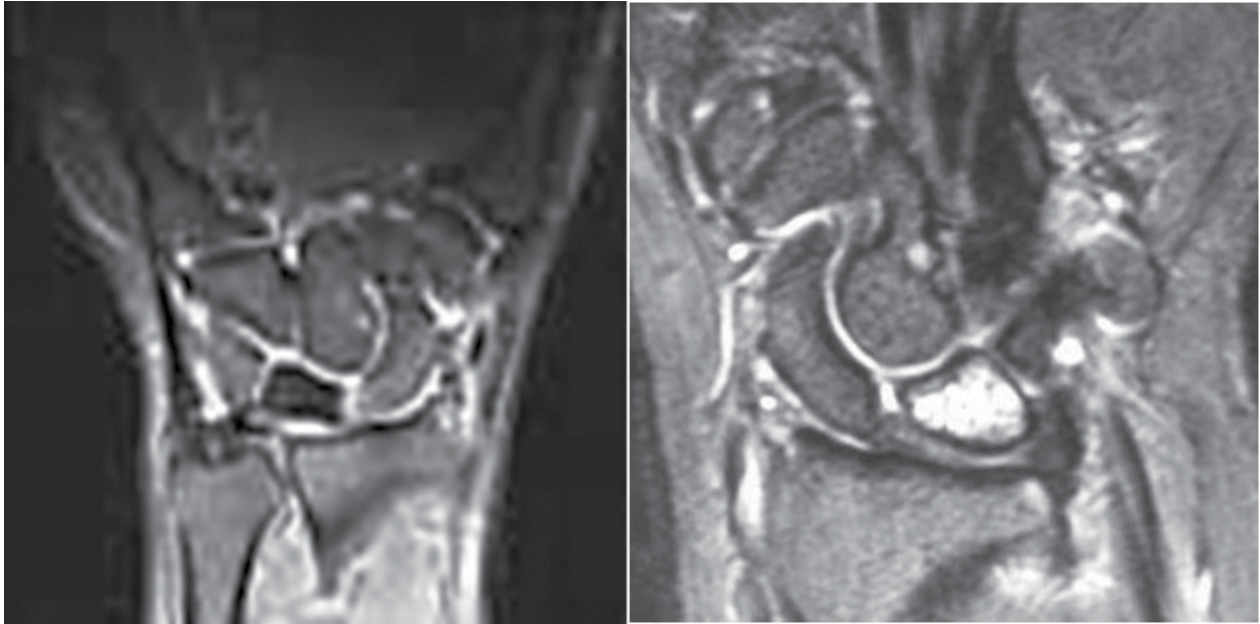


Figure 2. Lunate bone marrow edema in T2 and T1-weighted MRI.

TABLE 1. The widely used Lichtman classification

Stage	Description
Stage I	normal radiographs, normal architecture, marrow pathology in MRI
Stage II	lunate increasingly radiodense, sclerosis mosaic, overall structure preserved
Stage III	collapsed lunate
Stage IIIA	lunate with fragmentation, no associated carpal alignment changes, radioscapoid angle < 60°
Stage IIIB	carpal collapse and fixed scaphoid volar flexion, radioscapoid angle > 60°
Stage IV	lunate collapse with secondary pancarpal arthritis (midcarpal and/or radiocarpal joints affected)

proposed to describe KD, is based in radiological display of the lunate in plain X-rays and MRI findings (Table 1). In stage I lunate gives no pathological findings in radiographs, keeps normal architecture and only in MRI marrow pathology is present (Fig. 2). In stage II lunate becomes increasingly radiodense, displays a sclerosis mosaic but still the overall structure is preserved. Stage III is characterized by a collapsed lunate with multi-fragmentation lines present in radiographs as bone disorder progresses. This stage is further divided in two subgroups. In stage IIIA lunate appears collapsed with fragmentation lines but no associated carpal

alignment changes are present. For this stage radioscapoid angle is less than 60°. In stage IIIB there is carpal collapse and fixed scaphoid volar flexion with a radioscapoid angle more than 60°. Stage IV depicts lunate collapse with midcarpal and/or radiocarpal joints affected, described as secondary pancarpal arthritis (10, 11).

Wider use of MRI offered a more powerful tool allowing more persuasive investigation especially with the use of gadolinium. With this method differential diagnosis is more likely to be sensitive and accurate. Moreover, MRI proves helpful in recognizing the disease in initial stages providing the

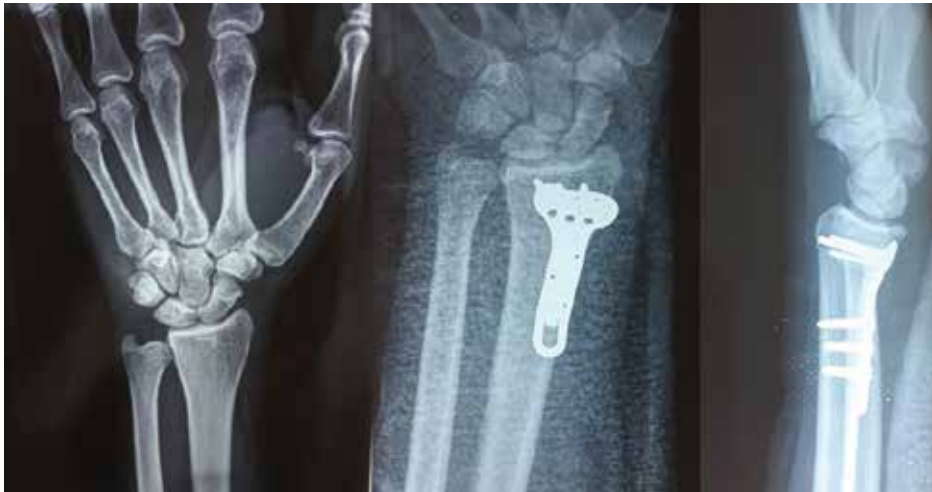

Figure 3. Patient with Kienböck disease stage I and negative ulnar variance treated with distal radius shortening osteotomy, preoperative and postoperative x-rays.

advantage to estimate prognosis and healing rate. Additionally, it appears to be a sensitive follow-up examination (12, 13).

Bain and Begg in 2006 proposed a different classification formed on the display of the lunate in arthroscopy. To be more specific, the disease is categorized by the number of joint surfaces that present degenerative changes and seem to be non-functional among the joints that lunate is involved in the wrist (14).

In other words, Lichtman classification focuses in bone integrity of the Lunate, Schmitt classification according to MRI images emphasizes in bone vascularity and Bain and Begg classification gives priority to cartilage condition and functionality.

Treatment

Conservative treatment

Most patients in initial stage tend to be treated conservatively for at least 3 months with immobilization, activity modification and anti-inflammatory medication. In this way, a sufficient time frame is assigned for revascularization and prevention of the progress of the disease. In case symptoms remain or there is deterioration in radiological examinations, radical medical therapeutic measures and operative procedures should be considered (15).

Non operative treatment is a preferable choice in children (<15 yo) and in elder patients (>70 yo)

especially in initial stage of the disease taking into consideration that provides better prognosis and healing rates.

Operative treatment

A great variety of operations has been suggested as KD therapy. Most popular among them involve: load redistribution, operations for revascularization, core decompression, arthrodesis of carpal bones, graft placement, wrist arthroscopy, arthrodesis of the wrist and wrist denervation. The main pathways that are commonly followed conclude to lunate unloading procedures, lunate revascularization, lunate or wrist reconstruction as salvage surgery.

Load redistribution operations are used to protect lunate from further collapse. In case of negative ulnar variance or flatter radial inclination or radially inclined lunate tilting angle, correction osteotomy of the distal radius is an established method to prevent the progression of the disease. In case of neutral or positive ulnar variance capitate shortening osteotomy is preferred offering satisfactory radiological and functional results (16, 17). For younger patients, radius shortening osteotomy (Fig. 3), before epiphysial closure observed, may lead to relevant recurrence. In children, with open growth plate, epiphysiodesis of the distal radius may be helpful and temporary scapho-trapezio-trapezoidal

pinning that unloads lunate while anticipating for revascularization is an alternative (18, 19).

Revascularization techniques with the use of intercompartmental or extracompartmental artery bone graft, 2nd or 3rd metacarpal base bone graft, vascularized pisiform bone graft, volar bone grafts from the distal radius or free bone grafts from the medial femoral condyle or iliac crest produce promising results and significant clinical recovery (20).

Core decompression is possible to be performed with an open technique or during arthroscopy. The main goal is to reduce intraosseous pressure and venous congestion to achieve indirect revascularization. Some authors suggest this method combined with bone grafts and arthroscopic debridement of synovitis (21, 22).

For patients in advanced stages, with higher possibility for lunate collapse, therapy is based on the potential for bone reconstruction. It is crucial to maintain the height of the proximal carpal row and ensure functional joint surfaces. The most essential difficulty is the high failure rates that accompany reconstruction techniques with the use of free vascularized osteochondral grafts (23, 24). Lunate reconstruction may be performed with the use of bone cement to prevent collapse (25).

In cases with lunate collapse, independent the functionality of articular surfaces, various methods have been proposed for interposition. Silicon, metal and pyrocarbon implants, tendinous grafts and Pisiform transfer have been utilized for this purpose (26-30). Lately, 3D printed implants have been produced, corresponding to CT depict of the non-affected hand (31). Capitate lengthening and proximal proximal row carpectomy are alternatives when the lunate is not reconstructable but joint surfaces of the

lunate facet and the capitate remain functional (15).

In late stages, with midcarpal and radiocarpal articulation compromised, radioscapolunate fusion, scaphocapitate fusion and hemiarthroplasty offer a choice for wrist reconstruction with prerequisite some joint functionality. For patients with established pan-arthritis wrist fusion and wrist arthroplasty may be applied depending (15).

Arthroscopy has been primarily used as a diagnostic tool for staging and classification of KD. Furthermore, it has allowed some therapeutic choices: synovectomy and debridement, lunate forage, radio-scapholunate fusion, scapho-capitate fusion, arthroscopic proximal row carpectomy. Graft placing can also be an arthroscopically assisted procedure (32, 33)

Wrist denervation complete or partial has been chosen as a therapeutic option by some authors. Results range and present a considerable variation despite the fact that there is a trend for improvement in functionality and pain relief. Another advantage is that wrist denervation permits additional surgical operations to be performed as adjuvant therapy (34, 35).

Conclusions

As far as the etiology of KD remains unknown, treatment strategies will present high variation among practitioners. Treatment is directly correlated to the disease staging. With technical advances new procedures are added to conventional tactics. Few treating algorithms are available but the final decision seems to come taking into consideration a main factor: patient's personal expectations. ▲

Conflict of interest

The authors declared no conflicts of interest.

REFERENCES

- Dumontier C. [Kienbock's disease. Current data]. *Annales de radiologie*. 1992;35(5):373-83.
- Irisarri C, Kalb K, Ribak S. Infantile and juvenile lunatomalacia. *The Journal of hand surgery, European volume*. 2010;35(7):544-8.
- Thienpont E, Mulier T, Rega F, De Smet L. Radiographic analysis of anatomical risk factors for Kienbock's disease. *Acta orthopaedica Belgica*. 2004;70(5):406-9.
- Chung KC, Spilson MS, Kim MH. Is negative ulnar variance a risk factor for Kienbock's disease? A meta-analysis. *Annals of plastic surgery*. 2001;47(5):494-9.
- Gelberman RH, Bauman TD, Menon J, Akeson WH. The vascularity of the lunate bone and Kienbock's disease. *The Journal of hand surgery*. 1980;5(3):272-8.
- Schiltenwolf M, Martini AK, Mau HC, Eversheim S, Brocai DR, Jensen CH. Further investigations of the intraosseous pressure characteristics in necrotic lunates (Kienbock's disease). *The Journal of hand surgery*. 1996;21(5):754-8.
- Kim S, Eichenauer F, Asmus A, Mutze S, Eisen-schenk A, Honigmann P. Superselective angiography of the wrist in patients with Kienbock's disease. *BMC musculoskeletal disorders*. 2019;20(1):143.
- De Smet L. Avascular necrosis of multiple carpal bones. A case report. *Chirurgie de la main*. 1999;18(3):202-4.
- Irisarri C. [Aetiology of Kienbock's Disease]. *Handchirurgie, Mikrochirurgie, plastische Chirurgie : Organ der Deutschsprachigen Arbeitsgemeinschaft fur Handchirurgie : Organ der Deutschsprachigen Arbeitsgemeinschaft fur Mikrochirurgie der Peripheren Nerven und Gefasse* 2010;42(3):157-61.
- Lichtman DM, Degnan GG. Staging and its use in the determination of treatment modalities for Kienbock's disease. *Hand clinics*. 1993;9(3):409-16.
- Lichtman DM, Lesley NE, Simmons SP. The classification and treatment of Kienbock's disease: the state of the art and a look at the future. *The Journal of hand surgery, European volume*. 2010;35(7):549-54.
- Schmitt R, Heinze A, Fellner F, Obletter N, Struhn R, Bautz W. Imaging and staging of avascular osteonecroses at the wrist and hand. *European journal of radiology*. 1997;25(2):92-103.
- Schmitt R, Kalb K. [Imaging in Kienbock's Disease]. *Handchirurgie, Mikrochirurgie, plastische Chirurgie : Organ der Deutschsprachigen Arbeitsgemeinschaft fur Handchirurgie : Organ der Deutschsprachigen Arbeitsgemeinschaft fur Mikrochirurgie der Peripheren Nerven und Gefasse* 2010;42(3):162-70.
- Bain GI, Begg M. Arthroscopic assessment and classification of Kienbock's disease. *Techniques in hand & upper extremity surgery*. 2006;10(1):8-13.
- Lichtman DM, Pientka WF, 2nd, Bain GI. Kienbock Disease: A New Algorithm for the 21st Century. *Journal of wrist surgery*. 2017;6(1):2-10.
- Chevrollier J, Pomares G, Huguet S, Dap F, Dautel G. Intracarpal shortening osteotomy for Kienbock's disease: A retrospective study of 28 cases. *Orthopaedics & traumatology, surgery & research : OTSR*. 2017;103(2):191-8.
- Yildirim AM, Piskin A, Karaismailoglu B, Sener M. Functional and radiological results of partial capitate shortening osteotomy in the treatment of Kienbock's disease. *The Journal of hand surgery, European volume*. 2020:1753193420905991.
- Jorge-Mora A, Pretell-Mazzini J, Marti-Ciruelos R, Andres-Esteban EM, Curto de la Mano A. Distal radius definitive epiphysiodesis for management of Kienbock's disease in skeletally immature patients. *International orthopaedics*. 2012;36(10):2101-5.
- Fontaine C. Kienbock's disease. *Chirurgie de la main*. 2015;34(1):4-17.
- Tsantes AG, Papadopoulos DV, Gelalis ID, Vekris MD, Pakos EE, Korompilias AV. The Efficacy of Vascularized Bone Grafts in the Treatment of Scaphoid Nonunions and Kienbock Disease: A Systematic Review in 917 Patients. *Journal of hand and microsurgery*. 2019;11(1):6-13.
- Bain GI, Smith ML, Watts AC. Arthroscopic core decompression of the lunate in early stage Kienbock disease of the lunate. *Techniques in hand & upper extremity surgery*. 2011;15(1):66-9.

REFERENCES

22. Menth-Chiari WA, Poehling GG, Wiesler ER, Ruch DS. Arthroscopic debridement for the treatment of Kienbock's disease. *Arthroscopy : the journal of arthroscopic & related surgery : official publication of the Arthroscopy Association of North America and the International Arthroscopy Association.* 1999;15(1):12-9.
23. Burger HK, Windhofer C, Gaggli AJ, Higgins JP. Vascularized medial femoral trochlea osteocartilaginous flap reconstruction of proximal pole scaphoid nonunions. *The Journal of hand surgery.* 2013;38(4):690-700.
24. Higgins JP, Burger HK. Osteochondral flaps from the distal femur: expanding applications, harvest sites, and indications. *Journal of reconstructive microsurgery.* 2014;30(7):483-90.
25. Vallejo EC, Martinez-Galdamez M, Martin ES, de Gregorio AP, Gallego MG, Escobar AR. Percutaneous Cementoplasty for Kienbock's Disease. *Cardiovascular and interventional radiology.* 2017;40(5):793-8.
26. Bellemere P, Maes-Clavier C, Loubersac T, Gaisne E, Kerjean Y, Collon S. Pyrocarbon interposition wrist arthroplasty in the treatment of failed wrist procedures. *Journal of wrist surgery.* 2012;1(1):31-8.
27. Kato H, Usui M, Minami A. Long-term results of Kienbock's disease treated by excisional arthroplasty with a silicone implant or coiled palmaris longus tendon. *The Journal of hand surgery.* 1986;11(5):645-53.
28. Saffar P. [Vascularized pisiform transfer in place of lunatum for Kienbock's disease]. *Chirurgie de la main.* 2010;29 Suppl 1:S112-8.
29. Viljakka T, Vastamaki M, Solonen KA, Tallroth K. Silicone implant arthroplasty in Kienbock's disease. *Acta orthopaedica Scandinavica.* 1987;58(4):410-4.
30. Werthel JD, Hoang DV, Boyer P, Dallaudiere B, Massin P, Loriaut P. [Treatment of Kienbock's disease using a pyrocarbon implant: case report]. *Chirurgie de la main.* 2014;33(6):404-9.
31. Xie MM, Tang KL, Yuan CS. 3D printing lunate prosthesis for stage IIIc Kienbock's disease: a case report. *Archives of orthopaedic and trauma surgery.* 2018;138(4):447-51.
32. Bain GI, MacLean SB, Tse WL, Ho PC, Lichtman DM. Kienbock Disease and Arthroscopy: Assessment, Classification, and Treatment. *Journal of wrist surgery.* 2016;5(4):255-60.
33. MacLean SBM, Kantar K, Bain GI, Lichtman DM. The Role of Wrist Arthroscopy in Kienbock Disease. *Hand clinics.* 2017;33(4):727-34.
34. Braga-Silva J, Roman JA, Padoin AV. Wrist denervation for painful conditions of the wrist. *The Journal of hand surgery.* 2011;36(6):961-6.
35. Schweizer A, von Kanel O, Kammer E, Meuli-Simmen C. Long-term follow-up evaluation of denervation of the wrist. *The Journal of hand surgery.* 2006;31(4):559-64.

READY - MADE
CITATION

Mitsikostas PK, Syngouna SA, Aifantis ID, Palavos IS, Spyridonos SG, Giannoulis FS. Kienböck disease, current issues. *Acta Orthop Trauma Hell* 2020; 71(2): 77-83.

Ligament reconstruction and tendon interposition arthroplasty for the treatment of 1st Carpo-Meta-Carpal joint arthritis

Panagiotis N. Giannakopoulos¹, Konstantinos Kourkoutas¹, George Kasimatis², Nikolaos Vlachos-Zounelis³

¹Athens Medical Center, Upper Extremity and Microsurgery Unit, Athens, Greece

²Athens Medical Center, Athens, Greece.

³Athens Medical Group, Psychiko Clinic, Athens, Greece.

ABSTRACT

Arthritis of the basal joint of the thumb is the most common form of hand arthritis. Various operations have been described for surgical treatment of this type of arthritis, such as simple excision, excision with ligament reconstruction, use of autogenous or synthetic grafts and total joint arthroplasty. Although many authors believe that simple excision with or without interposition of tendon or synthetic graft is adequate, the technique of ligament reconstruction with tendon interposition (LRTI) offers an additional and important factor to avoid the subsidence of the 1st metacarpal.

Materials and Methods. Between 1995 and 2018, 115 patients with basal joint arthritis of the thumb underwent surgical treatment in our institution. Sixty-five of them underwent operation with a modified technique of Barton and Pellegrini, using a suture anchor for the attachment of half of the flexor carpi radialis tendon. This technique simplifies the operation, making it feasible for a wider range of hand surgeons. Additionally, the patients underwent tenotomy of accessory bands of abductor pollicis longus when present.

Results. Assessment of the results was based on pain reduction, grip and pinch strength, as well as on the improvement of thumb motion. Reduction of 1st metacarpal height and the deformity of the thumb were also evaluated. Complications were minor following this procedure.

Conclusions. Excision arthroplasty and ligament reconstruction with tendon interposition (LRTI) remains a gold standard for treatment of basal joint arthritis of the thumb. The modification of the technique with the use of a suture anchor instead of an intraosseous tendon graft, offers a significant simplification and should be considered as an attractive alternative. Tenotomy of the accessory bands of abductor pollicis longus may further improve the final clinical outcome.

KEY WORDS: Thumb, Arthritis, Ligament, Tendon, Reconstruction

CORRESPONDING
AUTHOR,
GUARANTOR

Panagiotis N. Giannakopoulos MD, Consultant Orthopaedic Surgeon, Upper Extremity and Microsurgery Unit, Athens Medical Center, 5-7 Distomou Str, 11525, Athens, Greece. Phone: 00302106105387 E-mail address: pgiannak@otenet.gr

Thumb carpometacarpal (CMC) arthritis, often referred to as “Rhizarthrosis”, is a very common pathology, especially in elderly women. The incidence is high, approximately 15% in the general population. The pathology is present in 25% of men and 40% of women over 75 years old. Lately, the use of mobile phones, especially typing for SMS, has increased the incidence of this degenerative disorder. Gervis in 1949, first described simple trapeziectomy for the treatment of the condition and pain relief (1). Since then, a lot of variations in the surgical technique have been described, in order to provide pain relief and improvement of the pinch strength the thumb.

CMC joint anatomy

Thumb CMC joint is a biconcave saddle joint and consists of the articulation between the base of the first metacarpal and the distal end of trapezium. Trapezium-trapezoid, scaphotrapezial and trapezium-index metacarpal articulations are functionally related to the CMC joint. The curved articular surfaces of the CMC joint allow for limited stability only, which is provided by the ligaments. These ligaments play an important role in the static stability and dynamic control of the joint. Although studies have described three to sixteen ligaments, only a few have been directly implicated in joint stability [1]. Controversy exists regarding the main thumb CMC joint stabilizer. Ladd L.A et al, in their study comprising thirty cadaveric hands, identified seven principal ligaments. Three capsular ligaments (the dorsal radial, dorsal central and posterior oblique ligament) referred to as “dorsal deltoid ligament complex”, are located on the dorsum of the CMC joint and are found consistently stout, two volar ligaments (anterior oblique and ulnar collateral ligament), and two ulnar ligaments (the first dorsal trapeziometacarpal and the intercarpal ligament). Their morphometric findings on the dorsal radial ligament revealed it is of primary importance concerning stability, disproving the principal importance of the anterior oblique ligament that corresponds more to a hypocellular and disorganized structure rather than a true ligament [2][3]. Moreover, taking into account that highly innervated ligaments are believed to have a significant role in joint stability, as well as in the neuromuscular and proprioceptive function of the joint

[4], the greater innervation of the dorsal ligaments compared with the volar ones, furthermore supports the importance of the dorsal ligaments as stabilizers of the thumb CMC joint [2,3].

The presence of Accessory Abductor Pollicis Longus Tendons (AAPLT) may also play a role in CMC joint stability and arthritis. Zancolli EA (5) and Brunelli (6) reported that the presence of an accessory abductor pollicis brevis tendon may result in CMC instability and arthritis. On the other hand, Bouchlis G (7) in 1997, Roh MS in 2000 (8) and Schlz CU IN 2002 (9), in their anatomic studies found no significant relationship between osteoarthritis of the basal joint of the thumb and the supernumerary slips of the abductor pollicis longus tendon.

Evaluation and treatment

In the first stages of arthritis, the most common symptom is pain at the base of the thumb during daily activities. At late stages, there is pain at rest, difficulty in pinching and grasping and the characteristic “Z” deformity. Standard radiographs (AP and lateral views), show joint space narrowing, presence of osteophytes and the hyperextension of the MCP joint. Differential diagnosis must be done from De Quervain’s syndrome, STT arthritis and scaphoid nonunion, with or without arthritis.

Eaton in 1969, suggested a staging system for the arthritis of the basal joint of the thumb. In stage I, we have normal joint at x-rays and we have only synovitis. In stage II, joint space narrowing appears, with osteophytes <2 mm. Stage III is characterized by joint space narrowing and osteophytes >2 mm. Finally, in stage IV scapho-trapezium joint space involvement is presented (10).

Conservative treatment in early stages is effective, and it includes non-steroid anti-inflammatory medication and application of a thumb spica cast. Injections, such as steroids or hyaluronic acid, are the second line of treatment.

Surgery for CMC arthritis is recommended when non-operative measures fail to control the pain and functional limitations imposed by the disease. Constant pain, deformity, loss of motion and loss of grip and pinch strength are the most common symptoms. Additionally, surgery is also suggested in cases where

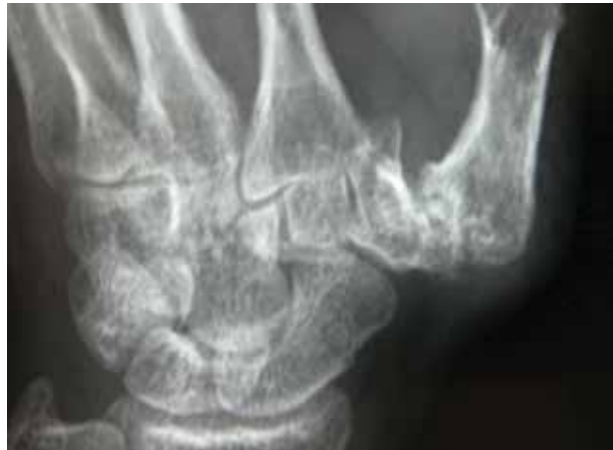
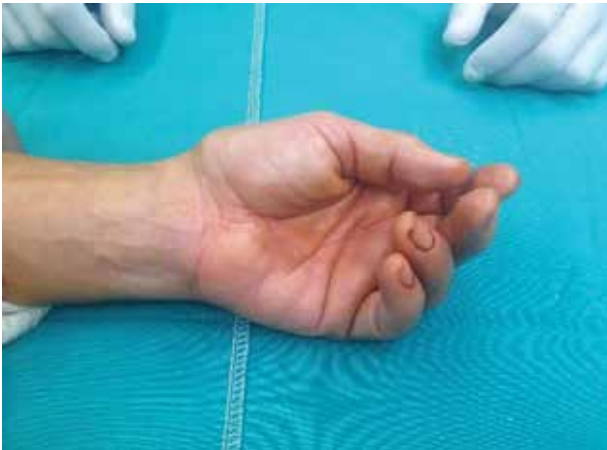
Fig 1, 2. Typical appearance of CMC arthritis

there is a failure from a previous arthroplasty (pain, dislocation), as well as in some relative indications (younger patient who requires grip and pinch strength in his/her work activity). There are a lot of surgical techniques for the treatment of CMC arthritis. The choice of the appropriate procedure for each patient is a challenging decision and it requires a lot of experience. In early stages of arthritis and with satisfactory articular surfaces, we could proceed to an AAPLT tenotomy or to ligament reconstruction with tendon graft, especially when instability and subluxation are present. Other options are arthroscopic debridement of the joint or a 1st metacarpal closing wedge osteotomy in dorsal extension (5).

For Eaton stage II - IV thumb CMC arthritis, the available procedures are listed below: simple trapezium excision called as "hematoma distraction arthroplasty", trapezium excision with ligament reconstruction and tendon interposition (LRTI arthroplasty), suture suspensoplasty, graft jacket / dura mater usage, total joint replacement, CMC denervation and fusion.

Haematoma distraction arthroplasty

Hematoma distraction arthroplasty is performed under general or regional anesthesia and using a tourniquet. A longitudinal or slight curved incision on the radial aspect of the wrist, along the radio-dorsal aspect of the thumb metacarpal and the axis of the APL and EPB, is carried out. Local branches of the radial sensory nerve and radial artery should be identified and protected during this approach. The incision is then

deepened in the interval between APL and EPB and the joint capsule is exposed on its radio-dorsal aspect. It is important to notice that we have to recognize the trapezium and to be sure that we will remove it alone because sometimes it is too difficult to separate it from the trapezoid or the base of the metacarpal. An osteotomy of the trapezium with an osteotome and a subsequent resection with a rongeur is performed. Additionally, FCR tendon must be identified in the deep layer and it should be carefully preserved. Complete removal of the trapezium should be attempted to avoid leaving behind any small bone fragments that may later cause pain with joint movements. The most important step is pinning of the thumb metacarpal in the proper position. With the thumb in wide palmar abduction, slight opposition, and distraction until firm resistance is encountered, a single 1.6-mm K-wire is passed from the thumb metacarpal base until it engages securely in either the base of the index metacarpal or in the trapezoid. Abduction and pronation of the thumb with the fingers and the thumb passively formed into a fist, the thumb tip should be pointed between the middle and ring fingers just distal to the proximal interphalangeal joints. In general, the space that will be eventually filled by the hematoma fluid, should allow just the insertion of the index fingertip of the surgeon. Postoperatively, a thumb spica cast is applied for 5-6 weeks and after this period we can remove the K-wire in order to start physiotherapy to restore the full range of motion and to strengthen the flexion - extension and abduction - adduction movements of the thumb (11).

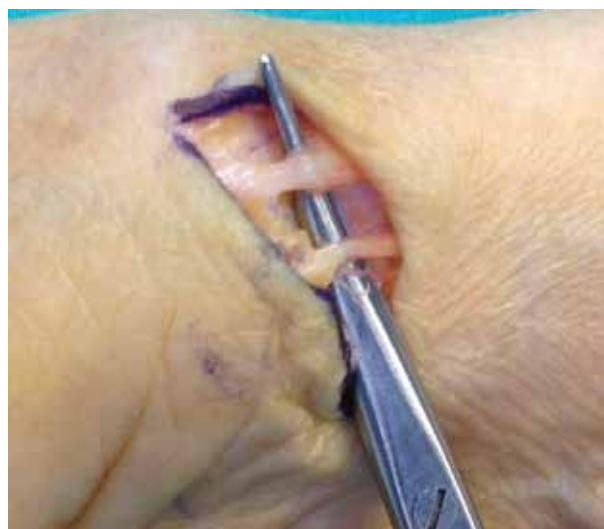
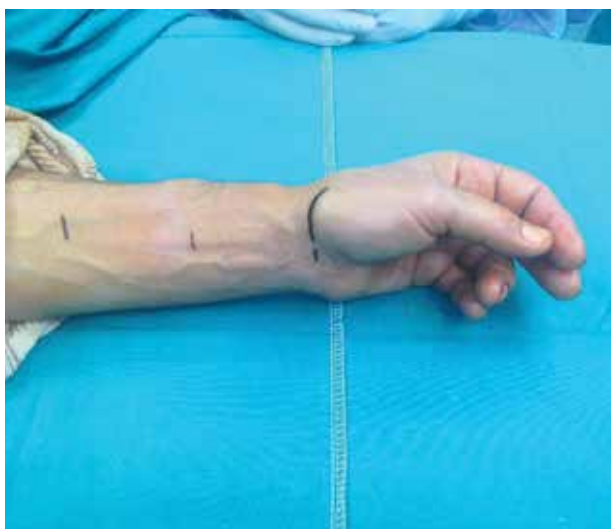
Fig. 3, 4. Palmar incisions and the identification of the radial nerve branches.

Ligament reconstruction and tendon interposition (LRTI) arthroplasty

Surgical management of basal joint arthritis of the thumb referred to as “Ligament Reconstruction with Tendon Interposition arthroplasty- LRTI”, was first suggested by Burton RI and Pellegrini VD in 1988 (12). They used a part of the FCR to stabilize the 1st metacarpal and to reconstruct the palmar oblique ligament. They reported excellent results in 92% of the cases. Weilby in 1988 reported that simple excision of the trapezium resulted in an unstable joint with telescoping motion, pain, weakness and a tendency to adduction deformity in 30% of the patients (13). He also suggested the stabilization of the 1st metacarpal using FCR and APL tendons. To achieve the reconstruction of the ligament and the stabilization of 1st metacarpal, different methods have been reported in the literature. Palmaris longus, Extensor Carpi Radialis Longus, as well as a combination of FCR and APL tendons are among others. But we have to notice that after careful study of these modifications, they do not present better outcomes than the initial procedure, which is based on the use of half of FCR tendon (14,15,16,17). Taylor N. in 2005, also reported a modification of the LRTI technique, replacing the bone tunnel with the use of a bone anchor for the entire FCR fixation (18).

Arthrodesis

Arthrodesis is performed through either a volar or

dorsal approach to the trapezio-metacarpal joint. With the joint distracted using traction on the thumb, the articular cartilage and the subchondral bone on the opposing surfaces of the trapezium and the base of the thumb metacarpal are removed. The remaining surfaces are then fused, supplemented with autologous bone graft harvested from the distal radius. The position for arthrodesis is such that the distal phalanx of the thumb is resting on the middle phalanx of the index finger of a fully clenched fist. Fixation is performed with multiple K-wires pins, tension band fixation, or a plate. Postoperative immobilization consists of a forearm-based thumb spica splint that is kept for six weeks. If K-wires pins are used, they are removed at six weeks, regardless of the radiological evaluation (19).

Allograft use

An alternative option to face up CMC arthritis in patients with Eaton stages III, and IV is the use of an allograft (Graftjacket or fascia lata), as the material for arthroplasty, in order to avoid the morbidity that has been associated with the harvest of the flexor carpi radialis tendon. Graftjacket is an acellular dermal matrix allograft which can be used instead of the FCR graft. Trapezium excision and identification of FCR are performed first. The allograft is then cut in order to create a 15-cm strip. The strip should be passed around the FCR and sutured at the base of 1st metacarpal through

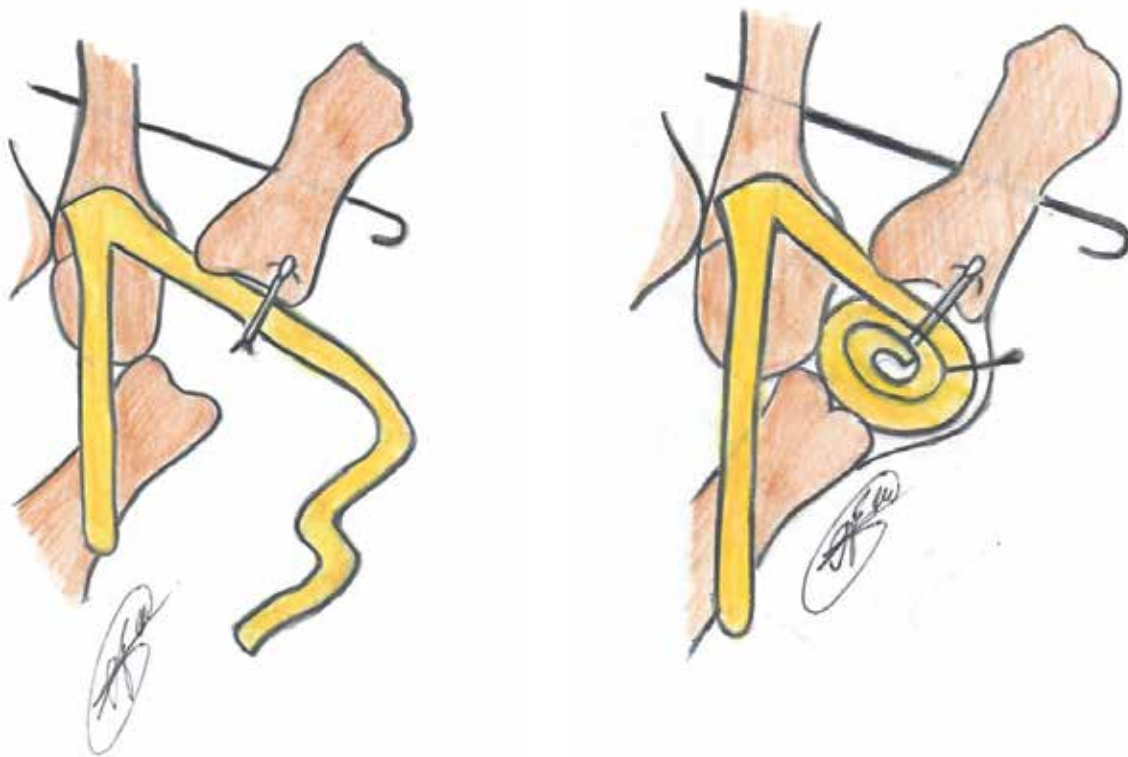


Fig. 5. Schematic representation of the surgical technique; depicts half of FCR fixation at the base of 1st metacarpal with a bone anchor.

a bony drill hole. The remaining portion of the allograft is fashioned as an interposition mass (anchovy) and is interposed between the scaphoid and the base of the first metacarpal. Postoperatively, same protocol as for the LRTI technique should be followed. The fascia lata allograft is also used as a “pillow” for interposition in the place of the excised trapezium, without ligament reconstruction (20,21).

Implant arthroplasty

In this method, all or part of the damaged thumb joint is removed and replaced it with an artificial implant. Silicone was the material which was used to design the first prostheses. In the more recent years, metal or pyrocarbon prostheses and cushioning synthetic spacers have prevailed in hand surgery. Older patients with lower demands may benefit from metal joint arthroplasties. On the contrary, young and active patients may have better outcome with the use of spacers. However, it must be noticed that although there

are some advantages from the use of implants, the rate of complications and the failure of implants (osteolysis, fracture, inflammation, persistent pain) is high. Till now, implant arthroplasty for CMC arthritis is not such a reliable method as the traditional procedures (22,23,24,25).

CMC denervation

The innervation of the first CMC joint is believed to arise from branches of the four principle nerves that surround it: the superficial branch of the radial nerve, palmar cutaneous branch of the median nerve, recurrent branch of the median nerve, and the lateral antebrachial cutaneous nerve. In selected patients, partial, volar first CMC joint denervation is possible with long term relief of pain and increased hand function (26).

Author’s preferred method

LRTI arthroplasty remains one of the most popular procedures for the treatment of CMC arthritis. The

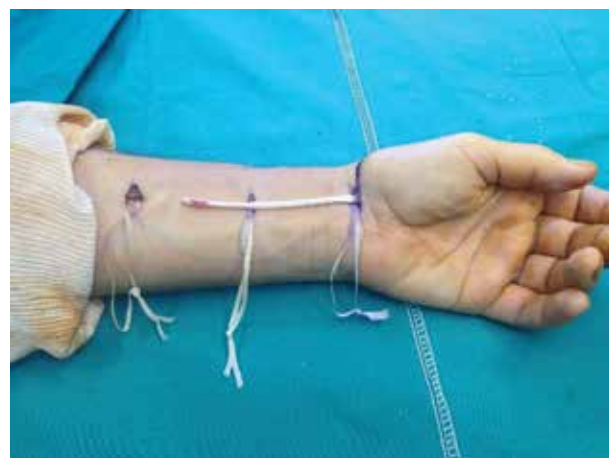
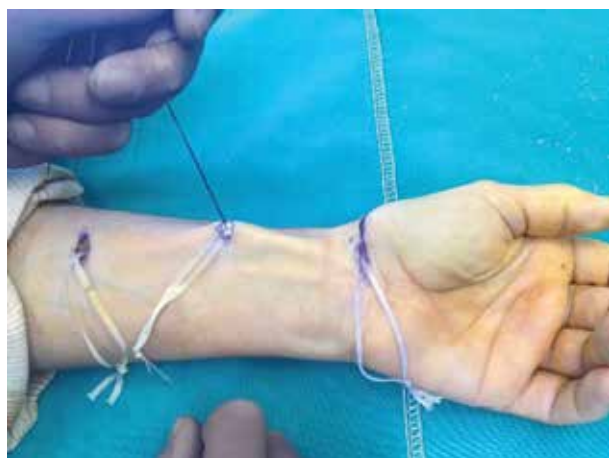


Fig. 6, 7. One half of FCR tendon harvesting.

goal of treatment is to excise the arthritic joint surfaces and to restore thumb metacarpal stability, along with reconstruction of the palmar ligament. In addition, tendon interposition reduces bony impingement. In our practice, we prefer a modified LRTI technique, harvesting half of the FCR tendon and fixing it at the base of the first metacarpal with a bone anchor. In patients with rheumatoid arthritis or other systematic disease, simple excision of trapezium is adequate.

Surgical note

The procedure can be performed under regional anesthesia. We prefer the palmar approach, as it is safer for the sensory branch of the radial nerve. Additional advantages are the protection of the dorsal ligaments and the better visualization of the FCR tendon. Moreover, it produces a more cosmetic scar. The dorsal approach, introduced by Burdon / Pellegrini has a higher risk for superficial radial nerve injury and it causes a less cosmetic scar. The superficial branches of the radial nerve must therefore be identified and protected.

We then proceed to AAPLT tenotomy, when accessory slips exist. Although there is no evidence based reports on the necessity for this tenotomy, we believe that the AAPLT is a possible contributing factor for the appearance of the 1st metacarpal collapse. Excision of the trapezium is the next step. Trapezium removal is not a simple stage of the procedure and removing the entire bone is not always effective. I prefer to create a big hole in the center of trapezium with a 4.5mm drill, which facilitates the easier and complete bone removal

in pieces with the use of a rongeur (Luer). C-arm fluoroscopy confirmation is useful. We must be very careful in order to remove all the bony fragments, because the presence of extensive osteophytes may sometimes cause difficulty in recognizing the articular surfaces, especially between the trapezoid and the trapezium. In addition, special care should be taken not to damage the FCR during trapezium excision. Extensive bone removal due to significant osteophytes (degenerative bone fusion) cannot usually lead to poor or fair results. The one-half of FCR tendon harvesting (radial aspect) must be performed. The half of the FCR tendon is harvested easier with the use of a strong suture placed within the tendon and separating it in the middle, through several stab incisions on the forearm. The tendon must be divided up to its insertion on the base of second metacarpal. The use of one-half of the FCR tendon prevents ulnar deviation of the hand. On the other hand, it may also provide a second option for ligament reconstruction in revision cases. However, in 2000, Varitimidis S. and Sotereanos D. (27) reported that the entire FCR could also be used, without significant hand morbidity. Reduction of the 1st metacarpal is very important and C-arm confirmation should be always performed. We perform the stabilization between the 1st and 2nd metacarpal as a standard procedure, using a 1.4 mm k-wire in 45° of abduction, flexion and rotation of the thumb. Ligament reconstruction of the 1st metacarpal is also important. The original technique requires creation of a tunnel for FCR fixation, which has some difficulties in its implementation. We

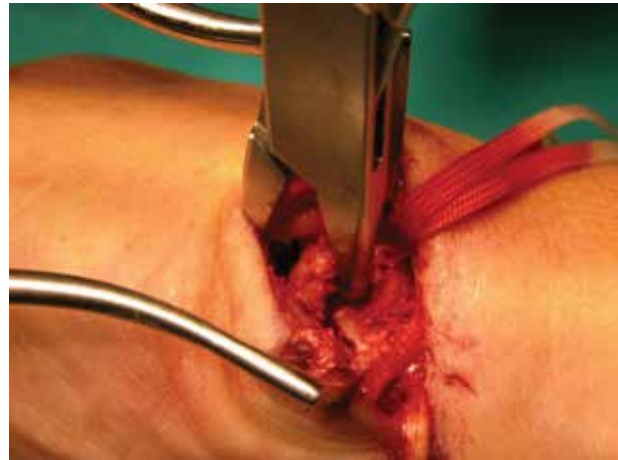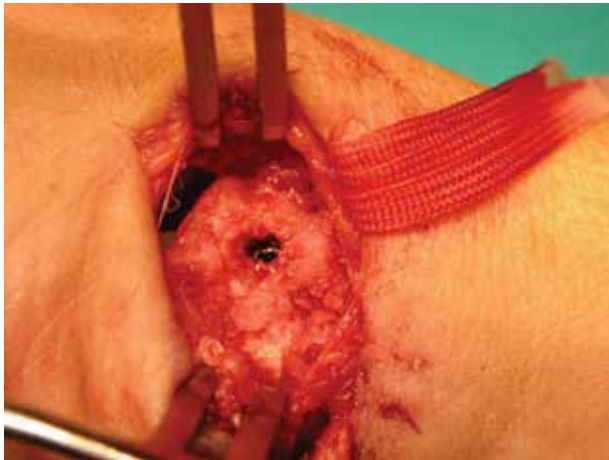


Fig. 8, 9. Trapezium removal after a big hole is drilled in the center of trapezium.

modified this technique by using a bone anchor, which simplifies the procedure and in addition, it reduces the surgical trauma to the capsule and the ligaments. The anchor placement should be in the radial and palmar surface of the base of 1st metacarpal, in order to substitute the palmar ligaments. The adequate tension of the graft is crucial and we must avoid over tension. The remaining tendon is sutured with the capsule and the rest is placed as interposition mass in the trapezoid space. Finally, capsule repair should be performed. Blood drainage is used in every case.

De Quervain's disease, trigger finger and carpal tunnel syndrome are often associated with CMC arthritis and additional release may be necessary.

Postoperative management includes thumb spica cast for 6 weeks. After this period, the k-wire should be removed. Normally, the patient follows a self-rehabilitation program and physiotherapy is not necessary. Full activity is permitted after a period of 3 months.

The complications of the procedure are limited. The most common one is a proximal migration of the thumb, which leads to loss of strength (less than "hematoma arthroplasty") and to "Z" deformity (swan neck). Injury of the superficial branch of the radial nerve is less common with palmar incision. Others complications are FCR tendonitis, De Quervain's Syndrome and CRPS. Rare complications may be due to pin placement, pin track infection, pin migration or breakage, and 1st or 2nd metacarpal fracture. Excessive bone removal, as a part of trapezoid, may also be noted.

Materials and results

Between 1995 and 2018 more than 115 patients with Eaton stage II-IV arthritis of basal joint of the thumb were treated surgically by the senior author (P.N.G.). There were two groups. First group of 40 patients was operated between 1995 and 2004 using the technique which was described by Burton and Pellegrini. Between 2005 and 2018, a second group of 65 patients was operated with the modified technique using a bone anchor. Proportion of women and men was 8:2 and the average age was 65 years (range 55-76).

At the follow-up examination, the patients were evaluated for pain relief, grip strength, lateral and pulp pinch, as well as thumb motion. Migration of the 1st metacarpal was also measured. Pain relief was 94-96%, grip strength increased 87- 90% and the lateral pinch increased 77-80%. Height loss was 15-25 %. The tip of the thumb was able to touch the little finger in a percentage of 95-97% of patients. Mild "Z" deformity was noted in 6-8 % of the patients. The rate of complication was up to 5%, but the majority were minor and did not influence the final outcome. All patients returned back to their previous occupation and they would undergo the surgical procedure again, had they known the result in advance (data not published).

Discussion

Carpometacarpal joint arthritis of the thumb is a quite common condition, especially among women. The thumb has a multi-axial motion leading to premature degeneration. Although hereditary predis-

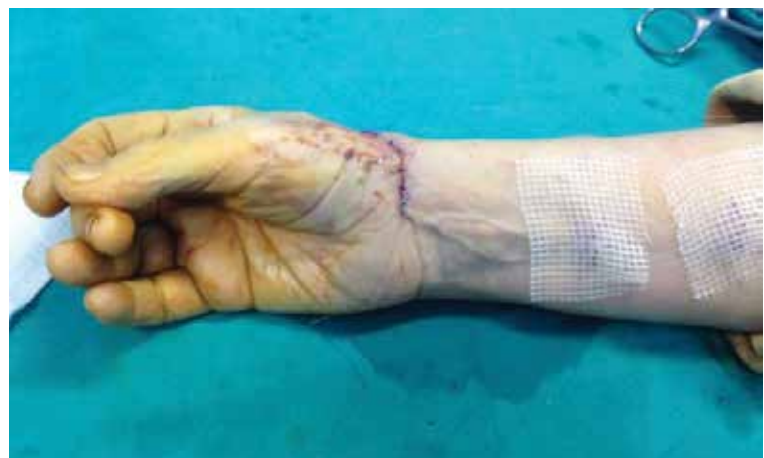
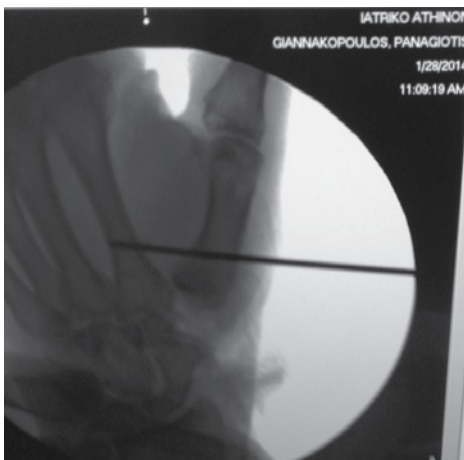
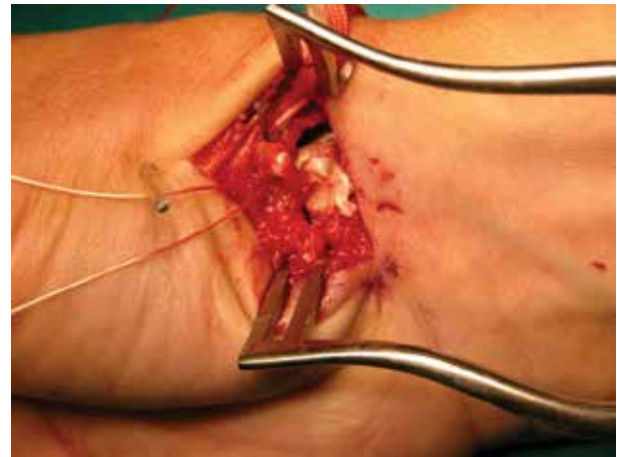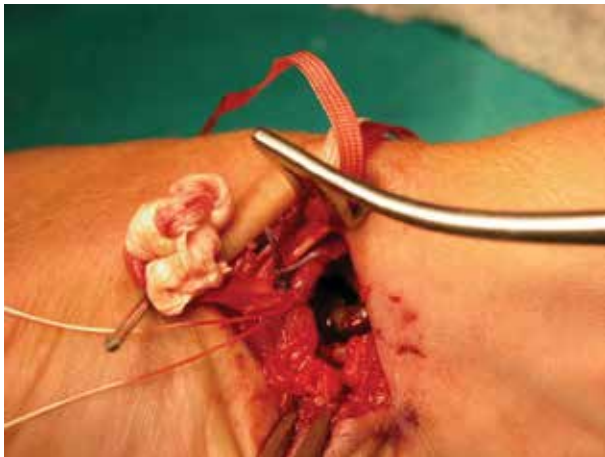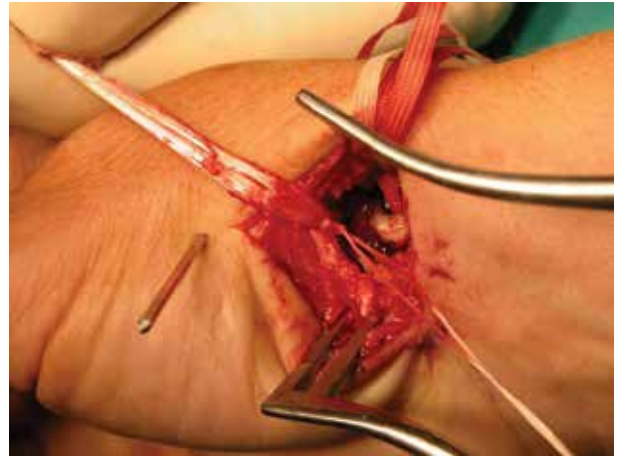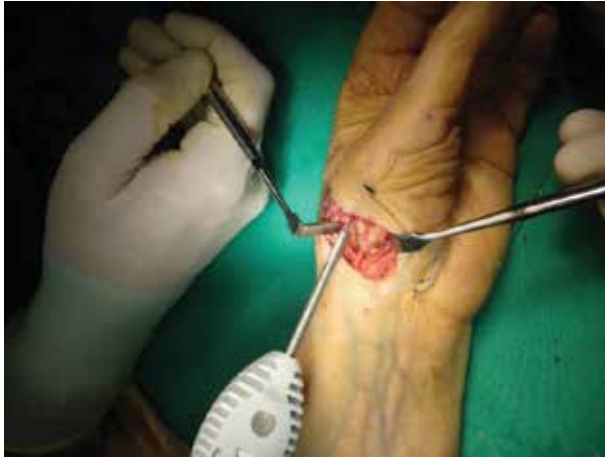Fig. 10, 11, 12, 13, 14, 15. Following the placement of the bone anchor, the FCR tendon is fixed on the base of 1st metacarpal. The remaining tendon is sutured with the capsule and the rest is placed as an interposition mass in the trapezium space. C-Arm confirmation of the stabilization between the 1st and 2nd metacarpal follows and the wound is finally closed.

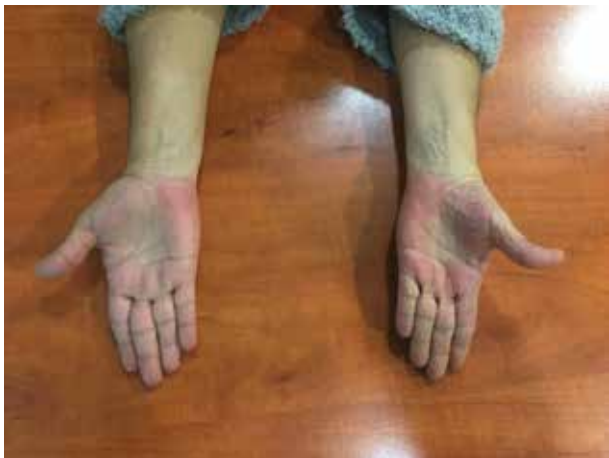
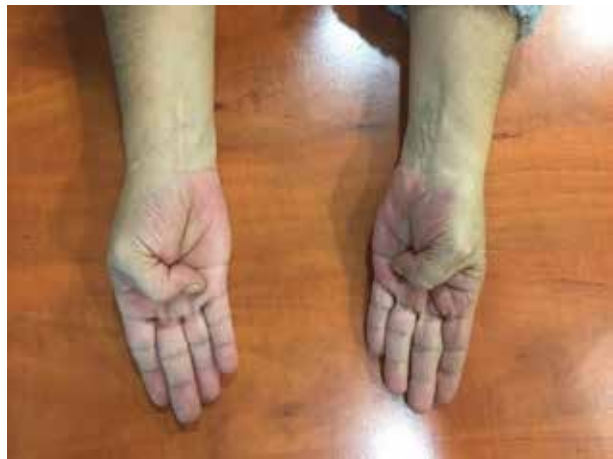
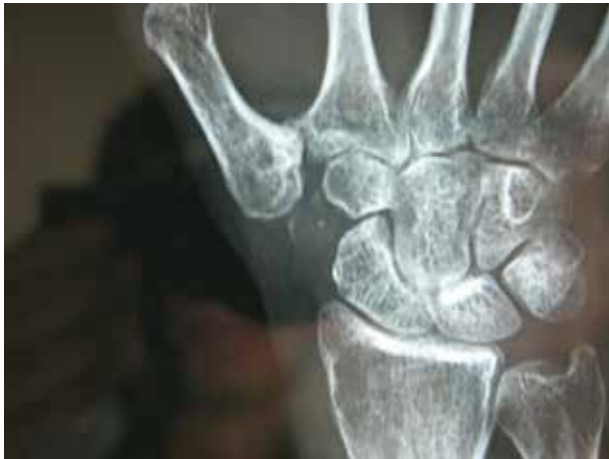Fig. 16, 17, 18. Three years' follow-up. No evidence of 1st metacarpal collapse is noted. The range of motion of the thumb is excellent.

position has not been established, the presence of the AAPLT may be of predictive value. The treatment is usually conservative and successful. Most of the times, it results to a painless type of "arthrodesis" with a degree of deformity of the thumb. Gradual "Z" shape deformity appears and, although it may decrease the functional ability of the hand, it is acceptable most of the times, especially among elderly patients.

The definitive treatment of CMC arthritis is surgical, as it happens in all other joint arthritis. The large variety of different surgical techniques underlines the complexity of its treatment. Simple trapezium excision also referred to as hematoma arthroplasty, is a popular and quite easy technique, with low degree of difficulty concerning rehabilitation (28). Nevertheless, this method usually leads to subsidence of the first metacarpal with the characteristic deformity, which dissatisfies especially the young and elegant women. The relative decrease

of the strength of the thumb, although it is most of the times acceptable, is an additional disadvantage of this particular method. We should also not neglect to report that some studies show no significant difference between the two methods, while others report a higher percentage of complications with the use of tendon for stabilization of the thumb. Total joint arthroplasty is more popular in countries where the designers of the prosthesis perform these replacements. When then are placed properly they result in a good functional outcome, but as with all implants, they have a restricted lifespan. In addition, more serious complications such as infection and periprosthetic fracture have been reported in the literature. The cost of the implants is also high, which is probable the reason why CMC arthroplasty has not globally prevailed over the other methods. The use of interposition materials like Graft jacket has also a high cost, while the results are not superior compared with the initial method of LRTI. Givisis P,

in 2016, published another method called “pillow” technique using a fascia lata allograft, which according to the author has very good results, however it is not widely recognized. Arthrodesis on the other hand can offer powerful hand grip with its known limitations.

LRTI remains for many surgeons the treatment of choice in such extent that it can be characterized as “traditional”. It provides a painless joint, while restoring the stability of the thumb on its anatomic position. Interposition arthroplasty has one more advantage concerning the subsidence of first metacarpal. The final result resembles more to the normal anatomy of the hand and it leads to a better cosmetic and functional outcome. Recent studies noted the importance of dorsal CMC ligaments on the stability of the thumb. Consequently, the preservation of these dorsal ligaments, which is achieved through the palmar approach to the CMC joint, allows for the good outcome. LRTI is a technique which was firstly described by Burton and Pellegrini on 1986. Weilby in 1986 described a modification of the method, while more modifications have been described by other authors. These techniques are effective but difficult for those with inadequate hand surgery training. The description of a simpler surgical technique, which can be performed by the majority of surgeons, while providing the same or even a better surgical outcome, can eventually promote hand surgery. According to this idea, the use of a single bone anchor which replaces the demanding procedure of bone tunnels for the stabilization of the thumb, greatly simplifies the procedure. There are a few studies comparing LRTI arthroplasty with and without bone tunnel which report similar long term result (Vermeulen GM, 2014) (29). In our experience however, a non-tunnel technique can provide a much better outcome with a lower rate of long term complications. Generally, the results of LRTI procedure are very satisfactory. In 1993, Nysten S reported that out of 100 patients treated with LRTI, the pain remained in only at 5 cases, 88 patients were satisfied with the procedure and there was a significant increase in pinch strength and in the ability to perform daily activities (30). In 1996, Lins RE reported an 89% satisfaction rate with pain relief, while 87%


of the patients would undergo this surgical procedure again. Loss of the trapezial space ratio did not decrease the final outcome. In 2000, Varitimidis SE referred that 95% of his patients reported excellent pain relief. A lot of other reports show similar results. Our experience may indicate slightly better results with the modified Burton’s and Pellegrini’s technique with the use of one anchor. On the other hand, comparing the LRTI technique with the simple excision, Naram et al, referred greater incidence of post-operative complications with LRTI group, but he did not compare the final outcome (31).

There are some critical points of the procedure that we should keep in mind. The procedure becomes simpler using a bone anchor, which also decreases the injury of the capsule and the ligaments. Although a slight loss of height of the 1st metacarpal does not indicate a poor outcome, a more serious collapse may result in deformity and functional limitations. The AAPLT tenotomy is not recommended by the literature, but in our opinion, the tenotomy can be useful. Our hypothesis is that as the accessory tendon is found in a large number of patients with basal arthritis of the thumb, and it may be the reason for palmar subluxation of the 1st metacarpal; especially the tendon branch to the thenar eminence, may be related to instability and arthritis. The tenotomy can reduce these forces and decrease the possibility of 1st metacarpal collapse without functional limitations. In our study presented in the annual meeting of HSSH in 2016, all our 16 patients with painful instability and/or primary arthritis of the basal joint of the thumb, were found to have an improvement of their symptoms after an AAPL tenotomy. These results are in agreement with the Zancolli study. In the end, tenotomy cannot have any negative impact. Another point of discussion is the appropriate duration and the method of thumb immobilization. Tendon to bone healing requires immobilization for a period of six weeks. All techniques with ligament reconstruction using tendon grafts (LRTI, Weilby) must follow this protocol. K-wire fixation of the 1st and 2nd metacarpals combined with a spica is a safer practice. Immobilization just with the thumb spica cast is not enough.

Conclusions

A great number of options have been described for the treatment of CMC arthritis. Trapezium excision and ligament reconstruction (LRTI) probably remains the most common and favorable technique. LRTI arthroplasty technique is safe, it provides adequate stability of the thumb, and it offers functional strength and motion. FCR fixation with a bone anchor as a minimal invasive

technique seems simple. Lower rate of risks and complications and slightly better results are noticed. However, there are also alternative options with excellent results and successful outcomes.

On the other hand, there are still some considerations. Is simple excision better than ligament reconstruction? Is an implant or an allograft better than autograft? Should we care about the cost? 

REFERENCES

1. Gervis WH: Excision of the trapezium for osteoarthritis of the trapezio-metacarpal joint J.B.J.S Br 31:537,1949Damen A, van der Lei B, Robinson PH. Carpometacarpal arthritis of the thumb. J. Hand Surg 1996; 21A: 807-812
2. Cardoso FN, Kim HJ, Albertotti F, Botte MJ, Resnick D, Chung CB. .Imaging the Ligaments of the Trapeziometacarpal Joint: MRI Compared with MR Arthrography in Cadaveric specimens. AJR. 2009; 192: W13-19
3. Ladd A, Lee J, Hagert E. Macroscopic and Microscopic Analysis of the Thumb Carpometacarpal Ligaments. J Bone Joint Surg Am. 2012; 94:1468-77
4. Ladd AL, Weiss AP, Crisco JJ, Hagert E, Wolf JM, Glickel SZ, Yao J. The Thumb Carpometacarpal Joint; Anatomy, Hormones, and Biomechanics. Instr Course Lect. 2013; 62: 165-179
5. Zancolli EA. The trapeziometacarpal joint. Tenotomy of the accessory tendons in early osteoarthritis. Hand Clinics 2001; 17(1): 13-43
6. Brunelli GA, Brunelli GR. Anatomical study of distal insertion of the abductor pollicis longus. Concept of a new musculo-tendinous unit: the abductor carpi muscle. Ann Chir Main Memb Super 1991; 10 (6): 569-576
7. Bouchlis GL, Bhatia AZ, Asfazadourian H, Touam C, Vacher C, Oberlin C. Distal insertions of abductor pollicis longus muscle and arthritis of the first carpometacarpal joint in 104 dissections. Ann Chir Main (Ann Hand Surg) 1997; 16 (4)4: 326-338
8. Roh MS, Strauch RJ, Xu L, Rosenwasser MP, Pawluk RJ, Mow VC, Thenar insertion of abductor pollicis longus accessory tendons and thumb carpometacarpal osteoarthritis. J Hand Surg (Am) 2000; 25(3): 458-63.
9. Schulz CU, Anetzberger H, Pfahler M, Maier M, Refior HJ. The relation between primary osteoarthritis of the trapeziometacarpal joint and supernumerary slips of the abductor pollicis longus tendon. J Hand Surg (Eu) 2002; 27B (3): 238-241
10. Eaton RG, Littler JW. A study of the base joint of thumb; treatment of its disabilities by fusion. JBJS 1969; 51A (4): 661-668
11. Gray KV and Meals RA. Hematoma and Distraction Arthroplasty for Thumb Basal Joint Osteoarthritis: Minimum 6.5-Year Follow-Up Evaluation. J Hand Surg 2007; 32A: 23-29
12. Burton R, Pellegrini VD. Surgical management of basal joint arthritis of the thumb. Part II. Ligament reconstruction with tendon interposition arthroplasty. J Hand Surg 1986; 11A: 324-332
13. Weilby A. Tendon interposition arthroplasty of the first carpo-metacarpal joint. J Hand Surg 1988; 13 (B), 4: 421-425
14. Davis TR, Brady O, Dias JJ. Excision of the trapezium for osteoarthritis of the trapeziometacarpal joint: a study of the benefit of ligament reconstruction or tendon interposition. J Hand Surg (Am) 2004; 29 (6):1069-1977
15. Lins RE, Gelberman RH, McKeown L, Katz JN, Kadiyala RK. Basal joint arthritis: trapeziectomy with ligament reconstruction and tendon interpo-

REFERENCES

- sition arthroplasty. *J Hand Surg (Am)* 1996; 21 (2): 202-209
16. Tomaino MM. Ligament reconstruction tendon interposition arthroplasty for basal joint arthritis. Rationale, current technique and clinical outcome. *Hand Clin.* 2001; 17 (2): 207-221
 17. Damen A, van der Lei B, Robinson PH. Carpometacarpal arthritis of the thumb. *J Hand Surg* 1996; 21A: 807-812
 18. Taylor N, Strauch R. Suture Anchor Arthroplasty for Thumb Carpometacarpal Osteoarthritis. *J Hand Surg* 2005; 5 (3): 153-158
 19. Hartigan BJ, Stern PJ, Kiefhaber TR. Thumb carpometacarpal osteoarthritis: arthrodesis compared with ligament reconstruction and tendon interposition. *JBJS* 2001; 83 (10): 1470-1478
 20. Kokkalis ZT, Zanaros G, Sotereanos DG. Ligament reconstruction with tendon interposition using an acellular dermal allograft for thumb carpometacarpal arthritis. *Tech Hand up Extrem Surg* 2009; 13 (1): 41-46
 21. Givvisis P, Sachinis NP, Akritopoulos P, Stavridis SI, Chrodoulou A. The "Pillow" technique for thumb carpometacarpal joint arthritis: Cohort study with 10 to 15 years follow-up. *J Hand Surg* 2016
 22. Minami A, Iwasaki N, Kutsumi K, Suenaga N, Yasuda K. A long-term follow-up of silicone-rubber interposition arthroplasty for osteoarthritis of the thumb carpometacarpal joint. *Hand Surg.* 2005; 10(1):77-82
 23. De Smet L, Vandenberghe L, Degreef I. Long-term outcome of trapeziectomy with ligament reconstruction and tendon interposition (LRTI) versus prosthesis arthroplasty for basal joint osteoarthritis of the thumb. *Acta Ortho Belg* 2013; 79 (2): 146-149
 24. Schmidt I. Treatment Options for Thumb Carpometacarpal Joint Osteoarthritis with an Update to the ArpeTM Prosthesis. *Recent Adv Arthroplast* 2018; 2(2): 55 – 63
 25. MacDermid JC, Roth JH, Gregory I, Bain GI. Trapezial arthroplasty with silicone rubber implantation for advanced osteoarthritis of the trapeziometacarpal joint of the thumb. *Can J Surg* 2003; 46 (2): 103-110
 26. Dellon AL. Volar denervation and osteophyte resection to relieve volar CMC joint pain. *Case Reports in Plastic Surgery and Hand Surgery* 2017; 4 (1): 13-16
 27. Varitimidis SE, Fox RJ, King JA, Taras J, Sotereanos DG. Trapeziometacarpal arthroplasty using the entire flexor carpi radialis tendon. *Clin Orthop Relat Res.* 2000; 370: 164-170
 28. Li YK, White TA, Thoma A. Comparison of trapeziectomy and trapeziectomy with ligament reconstruction and tendon interposition: a systemic literature review. *Plast Reconstr Surg* 2011; 128(1): 199-207
 29. Davis TR, Brady O, Dias JJ. Excision of the trapezium for osteoarthritis of the trapeziometacarpal joint: a study of the benefit of ligament reconstruction or tendon interposition. *J Hand Surg (Am)* 2004; 29(6): 1069-1077
 30. Vermeulen GM, Spekrijse KR, Slijper H, Feitz R, Hovius SER, Selles W. Comparison of arthroplasties with or without bone tunnel creation for thumb basal joint arthritis: a randomized controlled trial. *J Hand Surg* 2014; 39 (9): 1692-1698
 31. Nylen S, Johnson A, Rosenquist AM. Trapeziectomy and ligament reconstruction for osteoarthritis of the base of the thumb. A prospective study of 100 operations. *J Hand Surg (Br)* 1993; 18 (5): 616-619
 32. Naram A, Lyons K, Rothkopf DM, Calkins ER, Breen T, Jones M, Shufflebarger JV. Increased complications in trapeziectomy with ligament reconstruction and tendon interposition compared with trapeziectomy alone. *Hand* 2016; 11 (1): 78-82

READY - MADE
CITATION

Giannakopoulos PN, Kourkoutas K, Kasimatis G, Vlachos-Zounelis N. Ligament reconstruction and tendon interposition arthroplasty for the treatment of 1st Carpo-Meta-Carpal joint arthritis. *Acta Orthop Trauma Hell* 2020; 71(2): 84-95.

Traumatic brachial plexus injuries: our experience on 485 surgical cases

N.K. Daoutis¹, A.D. Vasileiadis², S. Spyridonos³

¹Consultant Orthopaedic Surgeon, Head of the Department of Hand Surgery & Reconstructive Microsurgery, Athens Metropolitan Hospital

²Consultant Orthopaedic Surgeon, Department of Hand Surgery & Reconstructive Microsurgery, Athens Metropolitan Hospital

³Consultant Orthopaedic Surgeon, Head of the Department of Hand Surgery & Reconstructive Microsurgery, Athens Accident Hospital K.A.T.

ABSTRACT

Traumatic injuries of the brachial plexus tend to, unfortunately, be quite frequent nowadays and often affect young adults. An increase in the number of traffic accidents, especially involving motorcycles, as well as, extreme sports accidents might be correlated to the increase of brachial plexus injuries. Although the research and statistical evidence on this topic is limited, the majority of our cases were involved in one of the two instances.

Initially, the clinician has to make observations in regards to the location of the lesion, the severity of the trauma in order to deduce an expected clinical outcome. The information is accordingly obtained through a detailed history of the accident, a thorough physical examination, as well as, imaging studies and specialised electro-diagnostic and nerve conduction investigations.

Precision in the timing of the surgery, along with the surgeon's knowledge and experience, as well as, the prioritisation of function restoration are of critical importance for the effectiveness of the treatment.

The surgical methods discussed in this article include the following: neurolysis, nerve repair with or without nerve grafts and nerve transfers for the restoration of the impaired functions of the upper limb. Based on our observations, it is important that the surgeon performing the operation is also the one deciding the recommendations for waiting and monitoring the injury.

This article will examine existing research on this subject but will mainly present the 485 cases the authors have treated over the last 25 years. Results will be analysed and discussed in order to present the factors influencing final recovery. It appears that time interval between injury and surgery, as well as, the number of roots involved in the trauma are most crucial.

KEY WORDS: Brachial plexus injury, adult, surgical strategy

CORRESPONDING
AUTHOR,
GUARANTOR

Antonios Vassiliadis, MD, Orthopaedic Consultant, Department of Hand Surgery & Reconstructive Microsurgery, Metropolitan Hospital, 9 Ethnarchou Makariou street, 185 47, Neo Phaliro, Greece, Tel: +302104809767, Fax: +302104809289, E-mail: anvassiliadis@gmail.com

Introduction

Brachial plexus is a complex network of nerves, responsible for the motor and sensory innervation of the upper extremity. It is formed in the posterior cervical triangle by the union of the ventral rami of 5th, 6th, 7th, and 8th cervical nerve roots and 1st thoracic nerve root (**figure 1**)

In each spinal segment, roots are formed from the union of the dorsal (sensory) and ventral (motor) rootlets that exit the spinal canal and pass through the corresponding intervertebral foramen.

This composite nerve network can be divided into roots, trunks, divisions, and cords. The roots, trunks, and divisions lie in the posterior triangle of the neck, whereas the cords lie in the axillary fossa. Cords are further divided into the major nerves of the upper extremity [1]

Brachial plexus injury (BPI) is one of the most distressing injuries for the patient. It can effectively impair function in one and sometimes two upper limbs, causing significant loss of motor and sensory function. Patients are, therefore, unable to perform activities of daily living. This, in turn, may lead to unemployment, financial difficulties, depression and in rare instances even suicidal urges [5]

The most commonly observed cases include young males who were involved in a motorcycle accident and were thrown off the vehicle, suffering traction between their neck and shoulder and, thus, damaging the brachial plexus to varying degrees.

It is crucial that these young individuals are treated as early as possible to the best of our ability. This is feasible with the use of modern techniques in microsurgery, provided that the patient is treated in time. Although, there are techniques available for late referrals, commencing the treatment early, makes a significant difference to the outcome.

This article examines the authors' experiences in the management of injuries to the brachial plexus, through the treatment of several cases of adult brachial plexus injuries.

History

One of the earliest descriptions of injuries to the brachial plexus can be found in Homer's Iliad, describing the battle between Hector and Tefros [2]. However, it

was not until this past century that attempts at reconstruction were reported.

The first known documentation of obstetric brachial plexus injury was by Smellie in 1764, who assumed that traction was the cause of the palsy [3].

The introduction of microsurgical techniques, micro-sutures and new developments in nerve repair and regeneration started a revival in the surgical repair of brachial plexus injuries led by pioneers like Narakas, Millesi, Allieu, Brunelli, Gu, Terzis, Doi, and others.[4,6,7,8,9]

Mechanism of Injury

Brachial plexus injuries most commonly affect the supraclavicular zone, while infraclavicular and retroclavicular lesions are less common [10].

It is more common to find the injury at the level of the roots and trunks than in the cords and terminal branches. Two level injuries may also occur and should be taken into consideration for a differential diagnosis. Avulsion injuries at the level of supraclavicular region are observed after violent lateral head and neck turn away from the ipsilateral shoulder, resulting in disruptions within the C₅, C₆ and C₇ roots or the upper trunk (**figure 2**)

According to the majority of the reports [9], 70% to 75% of traumatic brachial plexus injuries are located in the supraclavicular region. 75% of them involve total plexus lesions (C₅-T₁), C₅-C₆ root injuries account for 20-25% of traumatic BPIs, whereas isolated lesions of the lower roots (C₈-T₁) account for 2-3.5% of traumatic BPIs. Total brachial plexus injuries usually involve rupture of C₅-C₆ roots and avulsion of C₇-T₁ roots.

Based on our findings, BP injuries are divided into the following two main categories:

Total Damage : Refers to complete motor and sensory paralysis of the upper extremity, (with Horner sign positive). This was observed approximatively in 60% of all our patients (485). The investigation during surgery revealed avulsions of all the roots (C₅, C₆, C₇, C₈, Th₁) from the spinal cord.

Partial Damage: 40% of all patients (485) that were operated on, fall under this category. Avulsion or disruption relates to C₅ root only (3 cases), in 171 cases there was an avulsion and/or disruption of C₅ and C₆, whereas in 12 cases, avulsion and/or disruption of

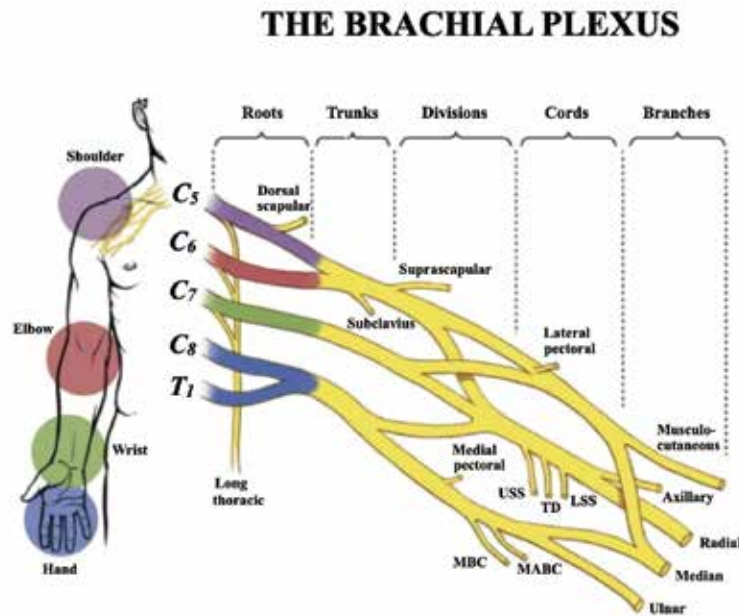


Figure 1: Anatomy of the brachial plexus.

$C_{5/6/7}$ was found, with the function of the lower roots (C_8 and Th_1) intact, therefore, maintaining the ability to fully move the hand.

Even though, open brachial plexus injuries were also observed (6 cases), they were much less common compared to closed BPIs. Lastly, iatrogenic lesions of the brachial plexus were reported (2 cases) during surgical procedures, including resection of the first rib, and carotid-subclavian bypass operations.

Diagnostic investigations

Imaging studies

Currently, plain X-ray films, computed tomography (CT) myelography, and magnetic resonance imaging (MRI) are being used as the main diagnostic tools.

Raised hemidiaphragm on plain X-ray films of the chest is suggestive of phrenic nerve injury.

The presence of pseudomeningocele on myelography indicates a root avulsion injury [11].

MRI provides general information about various components of the brachial plexus.

MR myelography is gradually replacing CT myelography in the diagnosis of root avulsions. However, false-positive pseudomeningoceles have been found in patients with intact rootlets, and false-negative re-

sults have been reported during surgical exploration.

Magnetic resonance neurography is a valuable tool in defining peripheral nerve anatomy and brachial plexus. Recently introduced high-resolution 3T MR neurography with three-dimensional imaging [12] is capable of illustrating the condition of nerve roots (avulsions or ruptures), defining the location and extent of injury in the distal part of plexus, as well as the regional denervation muscle changes. An abnormal enhancement of paraspinal muscles indirectly indicates a root avulsion injury.

Electrodiagnostic studies

Electrodiagnostic studies, are of utmost importance in the diagnosis and treatment of brachial plexus injuries [9], when there is good communication between the surgeon and the neuropathologist.

A normal muscle is silent at rest and active during contraction on insertion of electromyography (EMG) needles. Positive sharp waves and fibrillations indicate a denervated muscle, when the test is performed 2-4 weeks post-injury. Polyphasic low amplitude tracings are signs of reinnervation. An electromyographic evaluation of paraspinal muscles can differentiate root avulsions from root ruptures. Furthermore, fibrillation

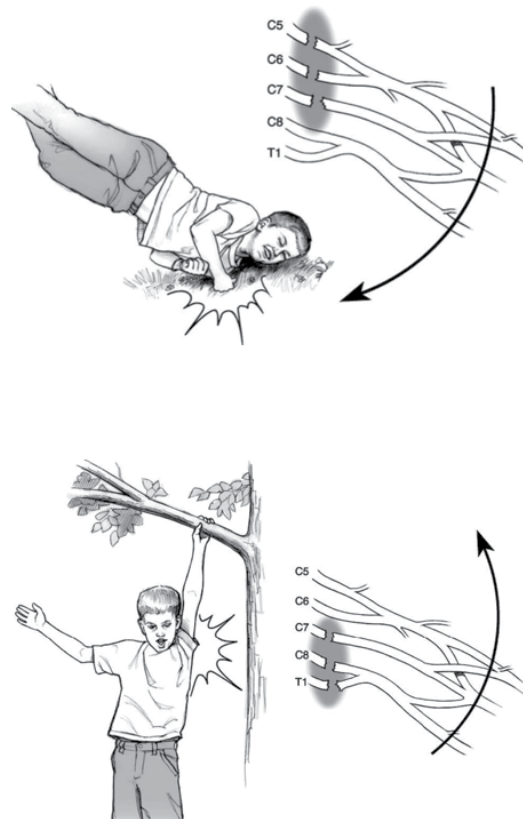


figure 2: Injury of the upper roots of the B.P. are due to violent lateral head and neck turn away from the ipsilateral shoulder whereas lower roots are injured when there is a forced abduction of the shoulder way beyond 90o.

potentials and positive sharp waves which are present in axonotmesis and neurotmesis are absent in neuropraxia injuries.

Microsurgical Reconstruction of Brachial Plexus Injuries

Timing of Surgical Procedure: The most critical point while planning a surgical procedure in brachial plexus injuries is the time passed between the accident and the intervention.

Instances which may require an emergency operative procedure include a vascular injury, open penetrating injuries at the level of posterior neck triangle (glass-knife), and open infected crushing/stretching wounds.

Treatment includes prompt restoration of the vessels as well (subclavian artery and/or vein).

An almost immediate surgical operation is, in turn, recommended within the first or second week for complete traumatic palsy of the C₅-T₁ root [5,13].

An early repair refers to the surgery performed within 8-12 weeks after the injury. The indications include a flail limb with severe deafferentation pain, the presence of pseudomeningoceles on magnetic resonance (MR) myelography, a positive Horner's sign, and a rapidly installed muscular atrophy.

In traumatic palsies with no clinical signs or electromyography data of functional recovery surgery is recommended after 3 months from the accident.

Perioperative assessment of the lesion is more accurate after Wallerian degeneration has occurred. Lesions related to iatrogenic aetiology should be surgically explored at an earlier stage, especially when electromyography reveals complete denervation with no signs of functional recovery

Operative techniques: The surgical treatment of BP injuries consists of the following: neurolysis in cases of fibrosis after a 1st degree injury, direct nerve repair in cases of direct injuries, bridging via nerve grafts in

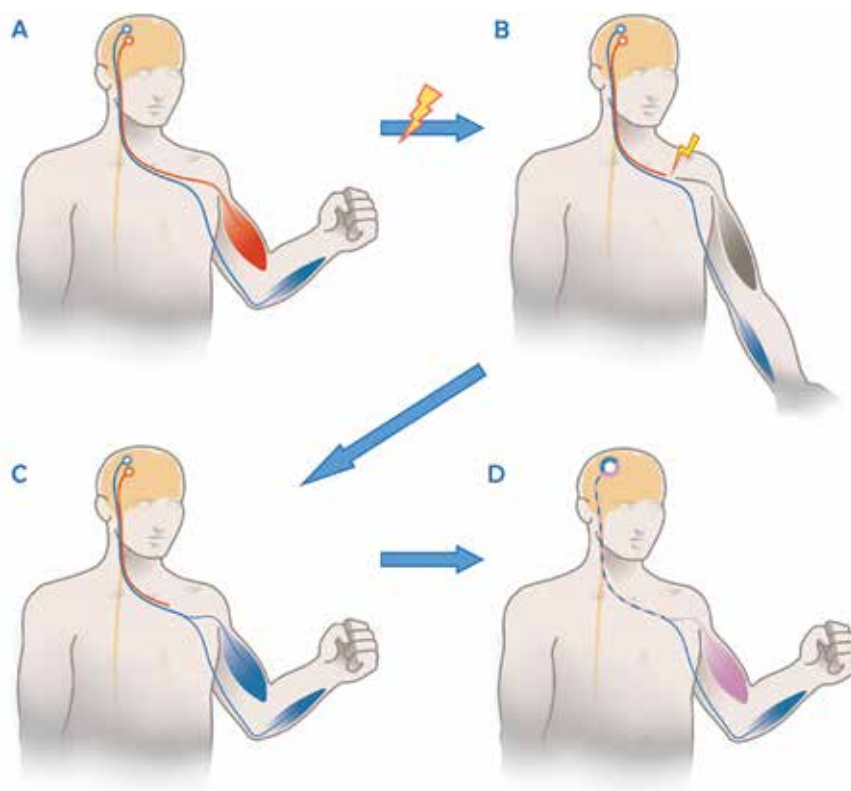


Figure 3: After an injury of the musculocutaneous nerve, the biceps muscle cannot be activated, while the uninjured ulnar nerve still functions. After the Oberlin's nerve transfer and re-innervation, fascicles of the ulnar nerve control the biceps muscles as well as all other muscles anatomically innervated by the ulnar nerve. Before cortical reorganization occurs, both muscles are activated together as there is no cortical separation between these nerve fibers. With rehabilitation, the patient learns to use certain cortical axons for "normal" ulnar nerve functions, while others are now controlling the biceps muscle. This allows independent movement of both muscle groups.

cases of nerve disruption, or neurotisation in cases of nerve or root avulsion.

Neurolysis is performed if an intraoperative nerve action potential (NAP) indicates regeneration. External neurolysis is carried out using a scalpel blade or Metzenbaum scissors. Nerve segments are freed circumferentially and in a proximal and distal direction from either side of the injured segment towards the centre of the damage.

If fascicular structure is found, but there is a large inter-neural gap, an end-to-end repair is not possible. An interfascicular repair is carried out by using sural nerve autografts.

A split-repair is performed when a portion of the element's cross-section exhibits more damage than the remainder of the element. The damaged segment is split away from the segment with more normal ap-

pearance and if no NAP is recorded across this damaged segment after it is split away, it is resected and repaired by graft. Excess scar tissue is removed from the segment to be spared, with care taken to not sacrifice the fascicular structure.

Neuroraphy : An end-to-end neuroraphy of the plexus branches is rare, and is used on clear lesions caused by glass or knife.

Among all our patients, this method was applied in 8 cases (6 lesions by knife/glass and 2 iatrogenic lesions).

Nerve Grafting : Nerve grafting is used in cases of disruption of nerve branches and in cases where there is a remaining stump of an avulsed root (6).

For a more precise direction of the axons from the proximal stump to the distal targets (neuromuscular junction, sensory particles), it is preferred to bridge the

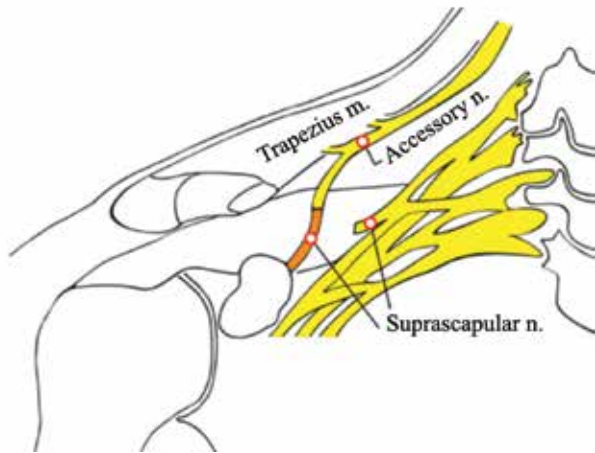


Figure 4: The distal branch of the accessory nerve is transferred to the distal stump of the suprascapular nerve.

central stumps with peripheral nerves (musculocutaneous nerve, suprascapular nerve, axillary nerve, medial nerve). In this way, a misalignment of the axons can be avoided. The nerves which can be used as nerve grafts are the following: the gastrocnemius (sural) nerve, the saphenous nerve, the medial cutaneous nerve of forearm, and the superficial radial nerve.

Neurotisation: In brachial plexus injuries, extraplexal nerves such as the spinal accessory nerve, the phrenic nerve, rami of the cervical plexus, or intercostal nerves may be coapted to trunks, cords or nerves the surgeon considers critical for reinnervation. Likewise, intraplexal nerves such as a group of fascicles from the ulnar nerve or the posterior cord (in cases of upper plexus injuries of the brachial plexus) can be used for the reinnervation of more important targets. A selective nerve transfer provides restoration of the motor function after a nerve injury, when recovery by the use of neurolysis, nerve repair, or nerve grafting cannot be expected.

Nerve transfers are indicated in avulsion injuries, when there is unavailability of an intact root as well as in cases of delayed reconstruction.

For a healthy individual, activity in the motor cortex of the central nervous system is clearly separated for every nerve [14]. As shown in the picture 3, there are two distinct areas on the cortex, each one corresponding to the ulnar and musculocutaneous nerve respec-

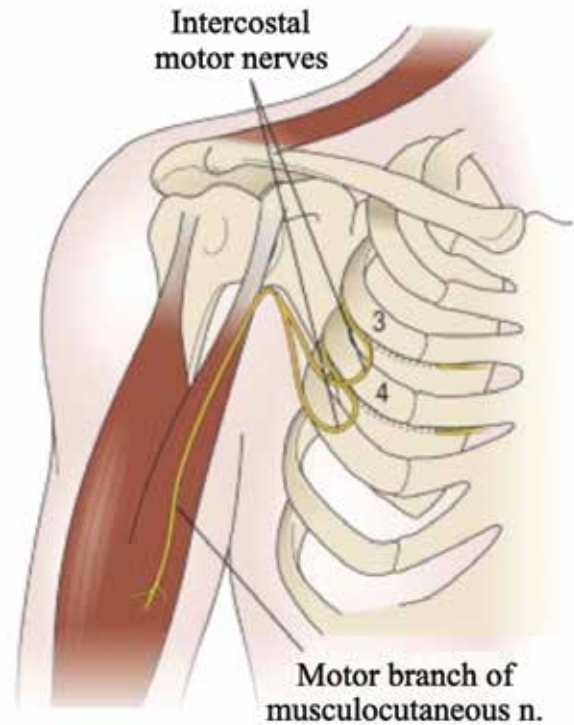


Figure 5: Two motor intercostal nerves are used to reinnervate the motor branch of the musculocutaneous nerve for the biceps muscle.

tively. After an injury to the musculocutaneous nerve, there is no activity of the biceps muscle, while the ulnar nerve still functions.

After the Oberlin's nerve transfer and the reinnervation, the cortical territory responsible for the function of the ulnar nerve activates the muscles innervated by the ulnar nerve and, at the same time, the biceps (figure 3). With successful rehabilitation and reeducation the patient learns to use certain cortical axons for the physiological ulnar nerve functions and at the same time others for the function of the biceps muscle [15].

Techniques in Avulsion Injuries on All Roots (C₅ - Th₁)

Motor and sensory paralysis of the entire upper extremity is challenging to treat. It is difficult to regenerate all the upper extremity muscle groups, given the absence of nerve donors, both cranial and spinal as well as the considerable distance between the donor site and the target organ.

Available nerve sources that have not been affected

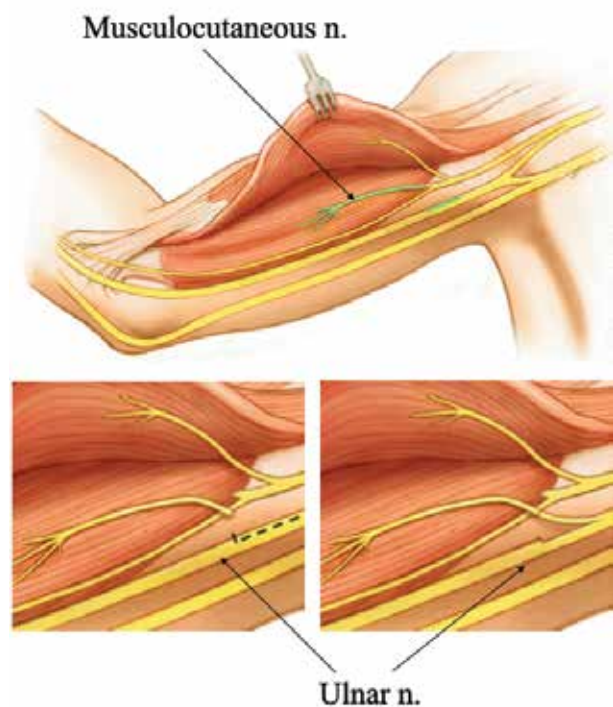


Figure 6: Transfer of one fascicle (or a group of two fascicles) of the ulnar nerve to the motor branch of the musculocutaneous nerve for the biceps muscle.

by the injury are the accessory nerve (distal branch), the phrenic nerve, the intercostal nerves, and the motor branches of the cervical plexus.

In a small number of avulsions, the C₅ root is rescued which, because of its large number of myelinated nerve fibers, provides valuable reinnervation to synergistic muscle groups. During the operation, the surgeon can evaluate the appropriateness of the nerve fibers (in conjunction with the anterior and posterior horns of the spinal cord). This is accomplished by stimulating the long thoracic nerve as well as the thoracodorsal nerve and assessing the state of the root (thickness, vascularisation).

The outgrowth of the two branches from the C₅ root is quite proximal inside the foramen, so if there

is a motor response from the respective muscles (serratus anterior, levator scapulae), then the root can be connected with safety with the peripheral nerves, using nerve grafts.

The main goal when it comes to an avulsion of all the roots of the plexus, is the independent movement

of the upper extremity, with shoulder stability and abduction, as well as, elbow flexion. For most patients, the lower branch of the accessory nerve (the whole trapezius muscle should never be denervated) (figure 4) and the phrenic nerve are used as donors.

In cases where one of the two donors is inadequate, then the intercostal nerves (Th4,5,6,7) are used for elbow flexion via nerve grafts (figure 5). Simultaneous use of the phrenic and intercostal nerves is avoided, in order not to affect the involuntary function of expansion of the hemithorax. The use of the phrenic nerve alone has not shown any postoperative problems in regards to respiratory function.

In addition, adequate shoulder abduction with a slight external rotation (subscapularis) can be achieved following the end-to-end suture of the suprascapular nerve.

The lower branch of the accessory via nerve graft is connected to the musculocutaneous nerve and provides reasonable flexion of the elbow, allowing contraction of the biceps under resistance (3+)

When both functions are restored (shoulder abduction - elbow flexion), secondary arthrodesis of the wrist is then recommended. This, in turn, ensures movement of the forearm and wrist as a whole.

Techniques in avulsions of the upper roots (C_{5,6,7})

In this particular form of injury of the brachial plexus, there is normal function of the hand thus, shifting the focus on shoulder-elbow neurotisation.

These cases are considered excellent in terms of prognosis, given the clinical findings following successful neurotisations within our Department.

So in cases of isolated C₅ avulsion, we carry out the neurotisation that will achieve shoulder abduction and external rotation (supraspinatus, deltoid, teres minor).

The phrenic nerve is connected by end-to-end suture to the suprascapular nerve.

Two bundles from the posterior cord are connected end-to-end to the axillary nerve.

If the injury also affects the A6 root then, elbow flexion is impossible (or difficult) to achieve.

In this case (C5, C6), through a distal incision up to the middle of the arm (picture 6) two bundles of the ulnar nerve (intraoperative motor control) are connected end-to-end to the motor branch of the musculocutane-

METHOD	No of patients	Supraspinatous	Biceps
SUPRASPINATOUS/BICEPS NEUROTISATION		M3 - M4	M3 - M4
Accessory	78	62	-
Phrenic	80	70	1
Ulnar	86	-	82

Table1: Reconstruction of shoulder abduction and elbow flexion through neurotisation of suprascapular and musculocutaneous nerves, from accessory, phrenic and ulnar nerves.

METHOD	No of patients	Receptors	M3 - M4
PLEXO-PLEXAL NEUROTISATION			
C ₅	22	Suprascapular	19
C ₅	34	Axillary	25
C ₅	26	Musculocutaneous	17
C ₅	8	Lateral cord	5
Posterior cord	26	Axillary	25
C ₇ (branch to triceps)	4	Suprascapular/ Axillary	4

Table 2: Table1: Reconstruction of shoulder abduction through neurotisation of suprascapular

The results from the remaining number of cases are still being examined and therefore, have not yielded conclusive evidence. However, a rough estimate indicates that their results are in accordance with the existing findings.

ous nerve (figure 6).

The distance of reinnervation is short (3-4 cm) and movement/response in the biceps is observed in the 5th month.

Avulsion of the C₇ root, which was observed in a few cases among our patients, was treated with tendon transfers (sublimis finger flexors, wrist flexors).

This group of patients with avulsion of upper trunks, when applying the aforementioned techniques, displayed an almost full shoulder-elbow reinnervation with a grade of (3+ - 4).

In 4 cases out of 184 upper type avulsions, the score was reduced to 3. In those cases, however, we were not able to control the cause of reduced nerve regeneration. Considering the complete intraoperative evaluation of donor nerves, the most likely cause would be some mechanical involvement of scar - connective tissue formation within the connections.

Post-operative management

Following surgery, the focus is to protect the nerve coaptation, reduce the oedema, and control the pain. Hence, careful attention is required and appropriate wound dressing is necessary. Initially, a bulky dressing is applied in order to protect the area of the nerve repair. The patient is advised to move only the joints not immobilised by the dressing. There is always a risk of applying external pressure to the wound that might cause a disruption at the level of the nerve or nerve graft coaptation. It might be difficult to detect such a disruption given the fact that it is a closed wound and the final result might be affected. It is the surgeon's responsibility, and not the nurse's, to ensure the upper limb stays properly immobilised. A nerve repair is typically immobilised for up to 3 weeks, compared to nerve transfers or grafts. Those are, in turn, performed with laxity so, the immobilisation is less rigid and

shorter in duration (typically 7–10 days). Nevertheless, we tend to maintain strict immobilisation for 3 weeks, in order to enable the proper healing of the nerve connections.

After 3 weeks, passive motion of the joints is initiated, while the nerve regeneration process is monitored monthly.

As soon as contractions of the restored muscles are observed, intensive physiotherapy with the use of exercises under resistance is recommended.

Systematic and long-term exercise plays an integral part in eliminating muscle atrophy and providing the desired cosmetic result.

Results

During a preliminary study of the first patients, we examined the outcome of 363 nerve transfers for avulsion injuries of the upper plexus. The patients were all males, with a mean age of 24 years (range = 19–40 years). Within the total number of nerve transfer cases (363), 251 were performed for shoulder abduction restoration and 112 for restoration of elbow flexion. An associated vascular injury was encountered in 12 cases. No perioperative complications were encountered. Muscle strength of the affected limb was checked preoperatively and was then reassessed every 2 months.

The last follow-up was after 3 years. The function/strength of the muscle was recorded on a 0 to 5 scale (with 0 indicating no muscle contraction and 5 indicating normal power). From 78 cases of accessory nerve transfer, 62 cases (79,5%) showed an improvement of supraspinatus muscle strength of M3–M4. From 79 cases of phrenic nerve transfer, 70 cases (88,6%) indicated an improvement of supraspinatus muscle strength of M3–M4. In one case, the phrenic nerve was transferred to the musculocutaneous nerve with nerve graft interposition. Postoperative assessment at 2 years showed improvement of the biceps muscle strength of M2, while at 3 years, muscle strength improved to M3+.

From 86 cases of ulnar nerve transfer to the musculocutaneous nerve (Oberlin's transfer), in order to restore elbow flexion, 82 cases (95,3%) showed excellent functional recovery of the biceps muscle (M3–M4). In 3 cases assessment showed an improvement of M2–3, while in one case no improvement was observed. (**Table 1**)

From 22 cases of C₅ transfer to the suprascapular nerve, 19 (86,4%) showed excellent result, from 34 cases of C₅ transfer to the axillary nerve 25 cases (73,5%) were evaluated as excellent, from 8 cases of C₅ transfer to the lateral cord 5 cases were evaluated as excellent, while 17 out of 26 cases of C₅ transfer to the musculocutaneous nerve had a score of M3–M4. The use of a group fascicle of the posterior cord and of a branch of C₇ for the reinnervation of suprascapular and axillary nerve proved to be a very good choice with 25 out of 26 (96%) and 4 out of 4 (100%) respectively resulting in a muscle strength of M3–M4 of supraspinatus and deltoid muscles (**Table 2**).

Conclusions

Amongst the patients that have been operated on within our department, avulsions were the most common injuries, usually caused by high acceleration accidents (fall during a motorcycle accident).

Immediate surgical treatment of BP injuries is recommended only in cases of open wounds of the posterior cervical triangle, with a clear cut of the nerves.

In open injuries that are associated with vascular damage (subclavian artery or vein), the repairing of the nerve can be postponed, since the vascular repair is the first priority.

In cases of extensive damage and when there are possible avulsions, clinical evaluation is needed, taking into consideration the patient's history, combined with electrophysiological examinations and imaging techniques. This can prevent an unnecessary surgery or delayed treatment that might have serious effects on the functional outcome.

The surgeon performing the potential microsurgical treatment should also be the one providing the recommendations for the waiting time and monitoring the injury. Unnecessary delays due to the long term nature of the results, might lead to defective muscle function or inconsistencies with the surgery.

Given the tight timeframe that muscles need to regenerate, the time between injury and its surgical treatment is valuable.


During surgery, the proximal nerve branches need to be thoroughly assessed with the use of electro-stimulation, since they act as donors for neurotisation. The possible involvement of these nerves in the in-

jury should also be noted in order to avoid using a damaged donor, which would lead to an ineffective reinnervation. The evaluation of the suitability of a nerve root and whether it can be used as a donor is dependant on the surgeon's experience. The length of the nerve graft does not appear to have an effect on the regeneration, however, if possible, an end-to-end connection between the donor and peripheral nerve is preferred.

The postoperative course should be monitored regularly by the surgeon himself or an experienced member of the team (once a month). Before the target

muscle is restored, the patient is encouraged to passively mobilise the joints. Intensive physiotherapy for the muscles with the use of resistance, significantly improves muscle strength. The regained function can further be improved in cases that allow for palliative surgery.

After 18 months the final result can then be evaluated.

To conclude a significant amount of our cases indicated an overall improvement after surgery, with an estimated 75% showing successful reinnervation of the paralysed muscles. 

REFERENCES

1. A. Kerr, "Brachial plexus of nerves in man. The variations in its formation and branches," American Journal of Anatomy, vol. 23, article 285, 1918.
2. Robotti E, Longhi P, Verna G, Bocchiotti G. Brachial plexus surgery: A historical perspective. Hand Clin. 1995;4:517-33
3. Smellie W. Vol. 3. London: Wilson and Durham; 1764. Collection of Preternatural Cases and Observations in Midwifery.
4. Narakas A. Surgical treatment of traction injuries of the brachial plexus. Clin Orthop. 1978;133:71-90.1.
5. Narakas AO. The treatment of brachial plexus injuries. Int Orthop 1985; 9:29-36.
6. Millesi H. Surgical management of brachial plexus injuries. J Hand Surg. 1977;2:367-78.
7. Narakas A. Brachial plexus surgery. Orthop Clin North Am. 1981;12:303-23.
8. Gu YD, Wu MM, Zhen YL, Zhao JA, Zhang GM, Chen DS, et al. Phrenic nerve transfer for brachial plexus motor neurotisation. Microsurgery. 1989;10:287-9.
9. Terzis JK, Papakonstantinou KC. The surgical treatment of brachial plexus injuries in adults. Plast Reconstr Surg. 2000;106:1097-122.
10. S.L. Moran, S.P. Steinmann, and A.Y. Shin "Adult brachial plexus injuries: mechanism, patterns of injury, and physical diagnosis," Hand Clinics, vol. 21, no. 1, pp. 13-24, 2005.
11. Abul-Kasim K, Backman C, Björkman A, Dahlin LB. Advanced radiological work-up as an adjunct to decision in early reconstructive surgery in brachial plexus injuries. J Brachial Plex Peripher. Nerve Inj 2010;5:14.
12. Chhabra A, Thawait GK, Soldatos T, Thakkar RS, Del Grande F, Chalian M, et al. High-resolution 3T MR neurography of the brachial plexus and its branches, with emphasis on 3D imaging. AJNR Am J Neuroradiol 2013;34:486-97.
13. Treatment Options for Brachial Plexus Injuries Review Article Vasileios I. Sakellariou,1 Nikolaos K. Badilas, ISRN Orthopedics Volume 2014, Article ID 314137, 10 pages
14. Structured Motor Rehabilitation After Selective Nerve Transfers. Sturma, A., Hruby, L. A., Farina, D., Aszmann, O. C. J. Vis. Exp. (150), e59840, doi:10.3791/59840 (2019).
15. Rehabilitation of the Upper Extremity Following Nerve and Tendon Reconstruction: When and How. Christine B. Novak, and Rebecca L. von der Heyde Semin Plast Surg. 2015 Feb; 29(1): 73-80.

READY - MADE
CITATION

Daoutis NK, Vasileiadis AD, Spyridonos S. Traumatic brachial plexus injuries: our experience on 485 surgical cases. *Acta Orthop Trauma Hell* 2020; 71(2): 96-105